


# 8. Východoslovenský biooptický seminár

## Prípád SDIAP č. 674

KOŠICE

Apríl 2018

Ľ. Straka



# ALPHA MEDICAL

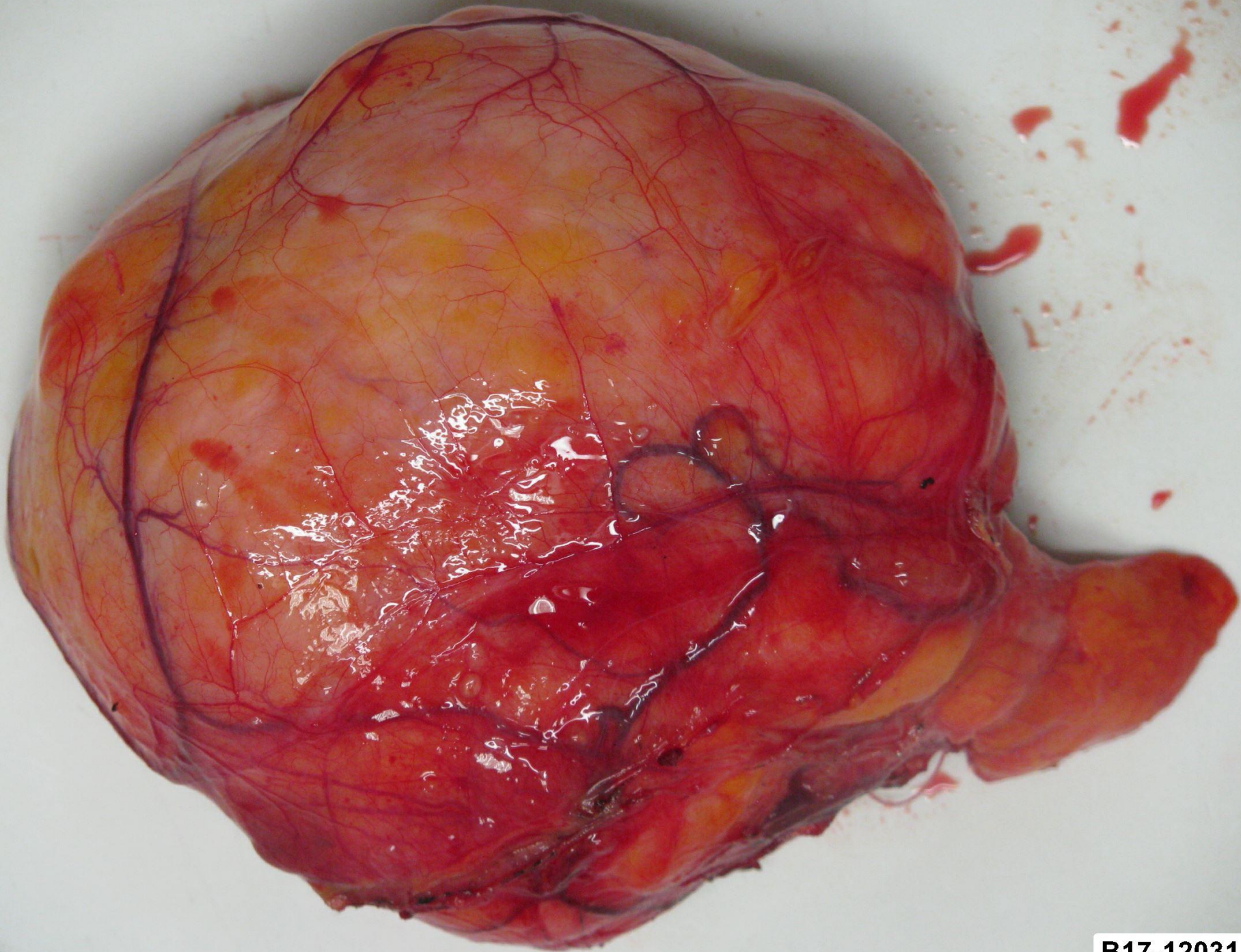


[straka.lubomir@alphamedical.sk](mailto:straka.lubomir@alphamedical.sk)

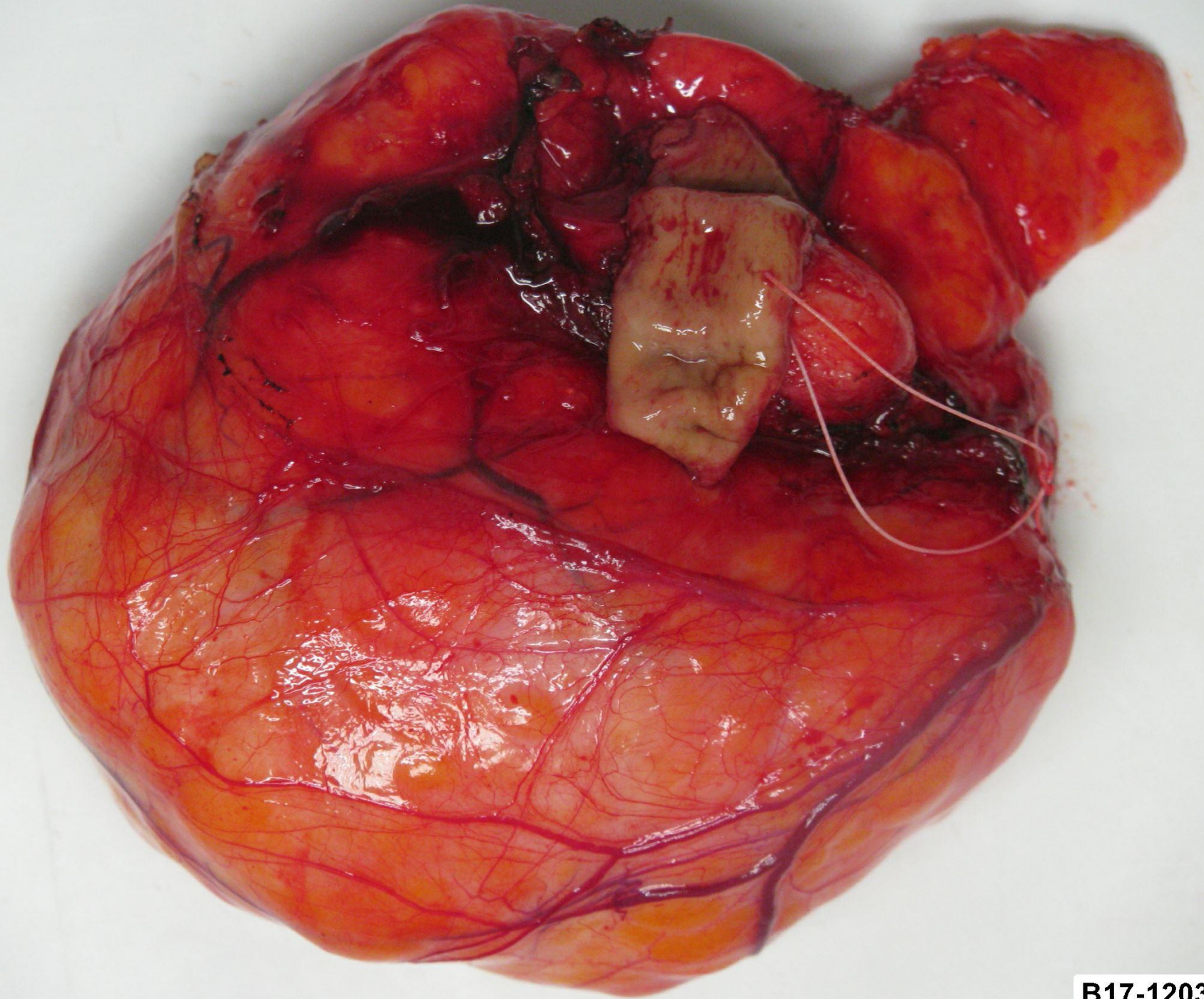
# SD-IAP č. 674

- 52 ročná žena
- tumor retroperitonea
- ovoidný nádor šedožltej farby 10 x 9 x 5 cm s priliehajúcou časťou žalúdka 4 x 2 x 0,3 cm

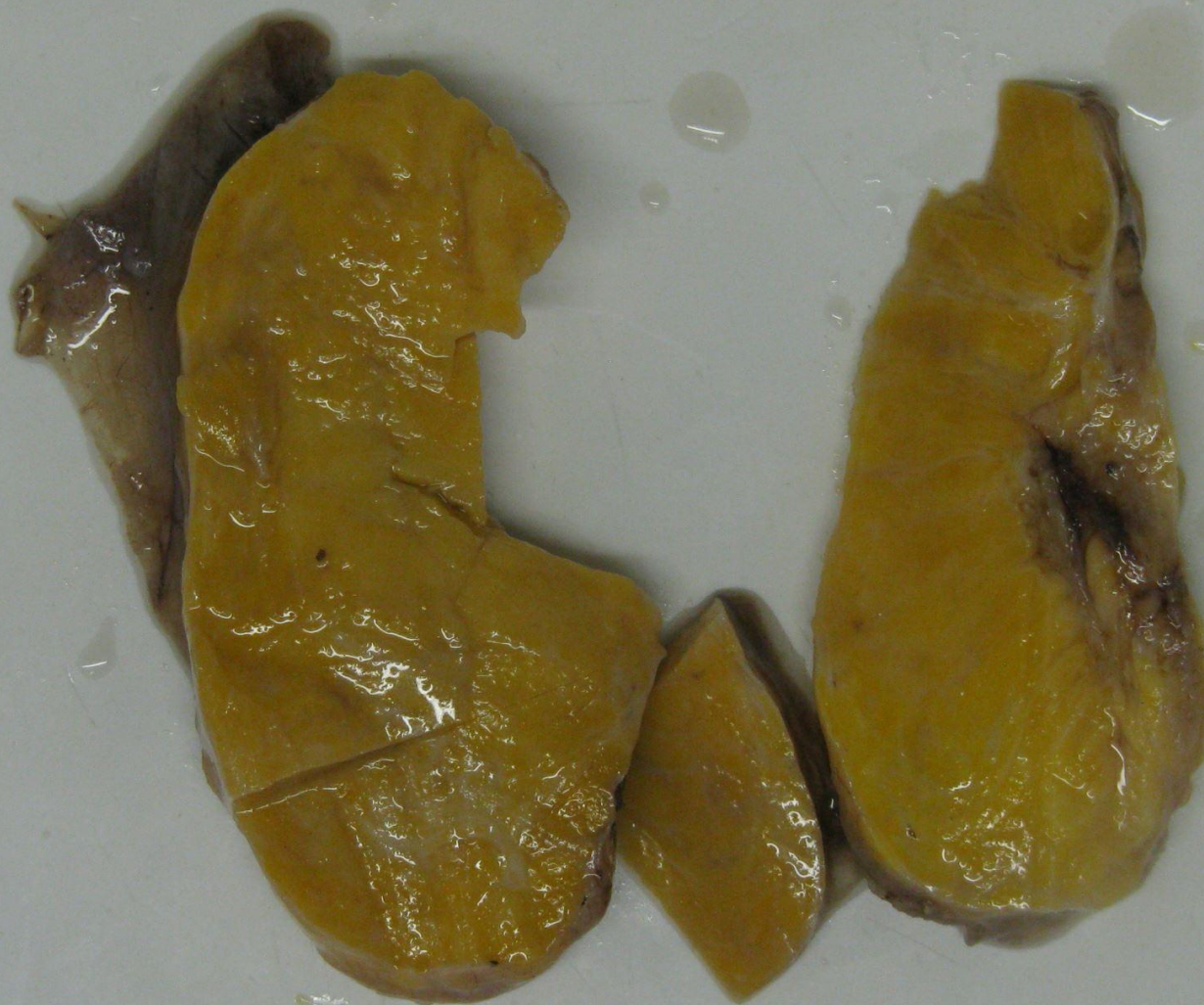GISTÓM ?



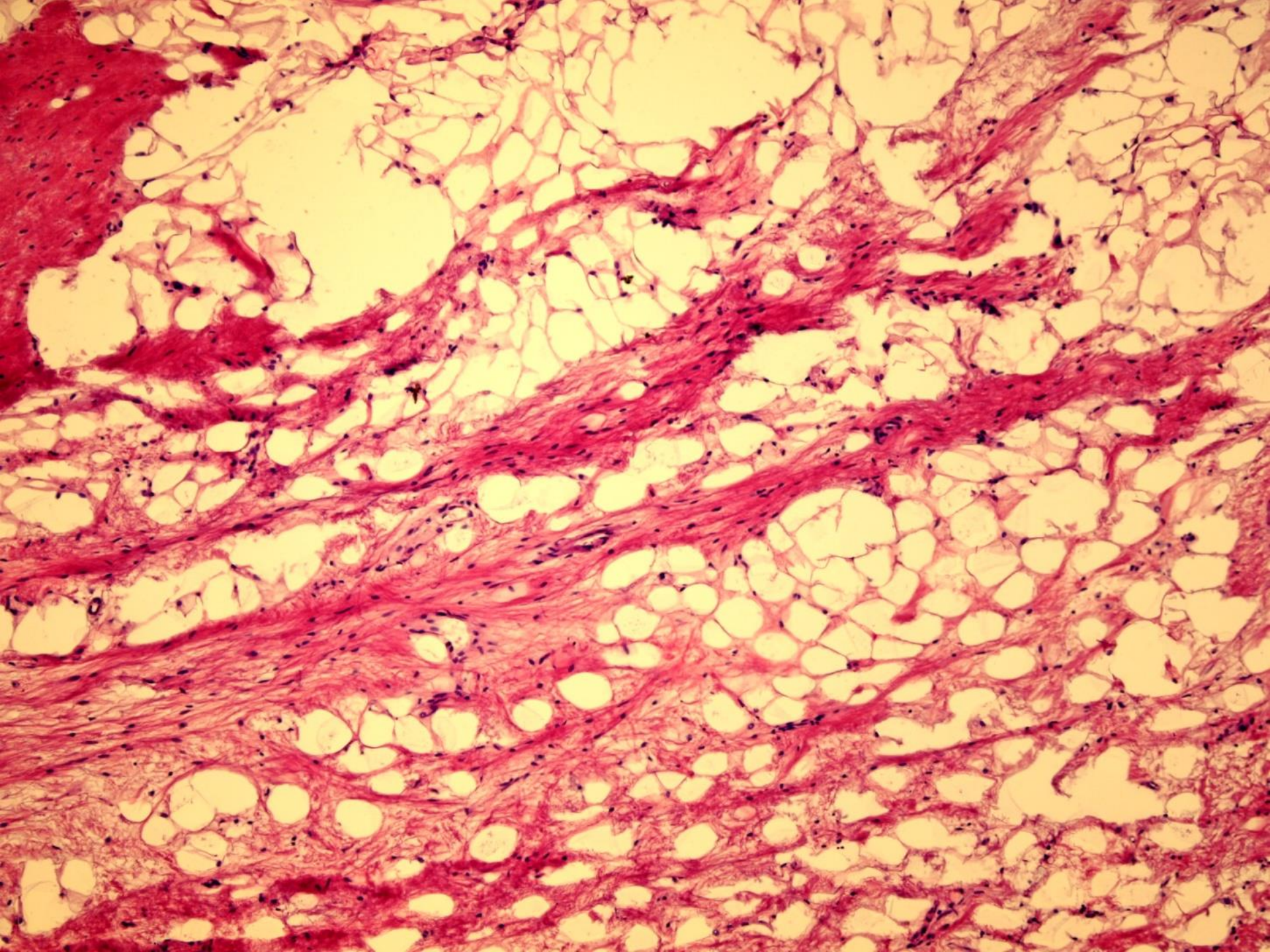
B17-12031

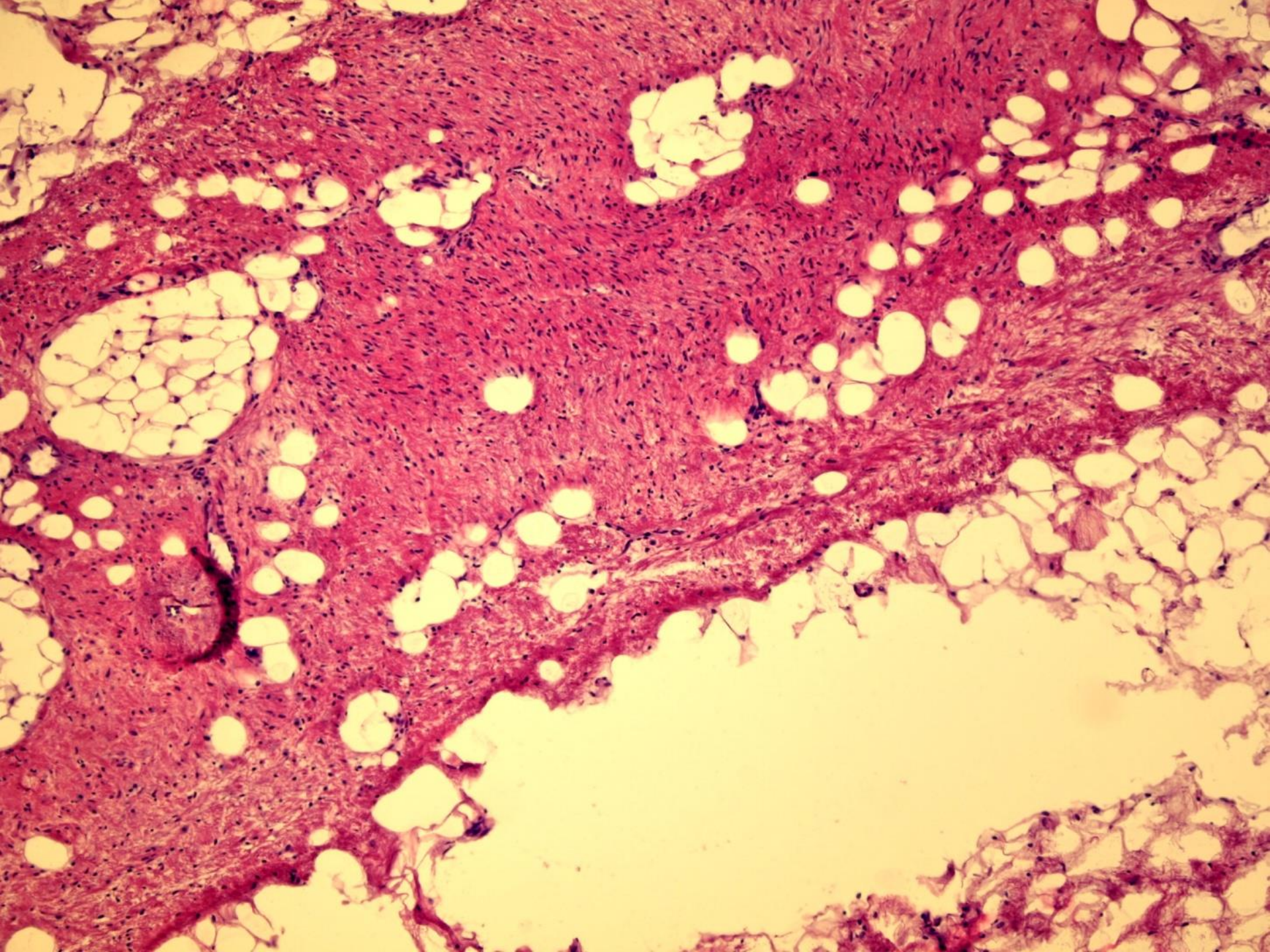


B17-12031



B17-12031



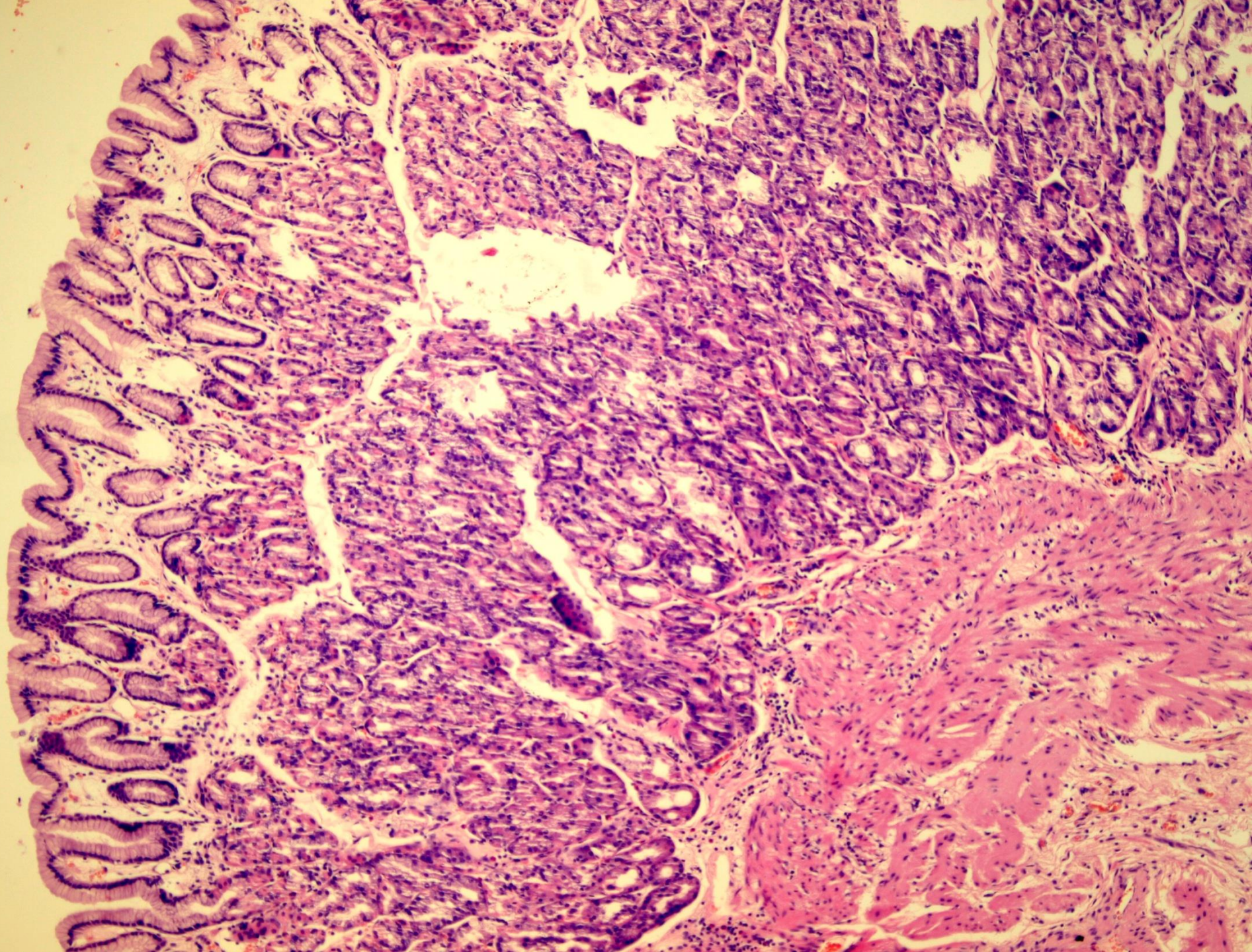


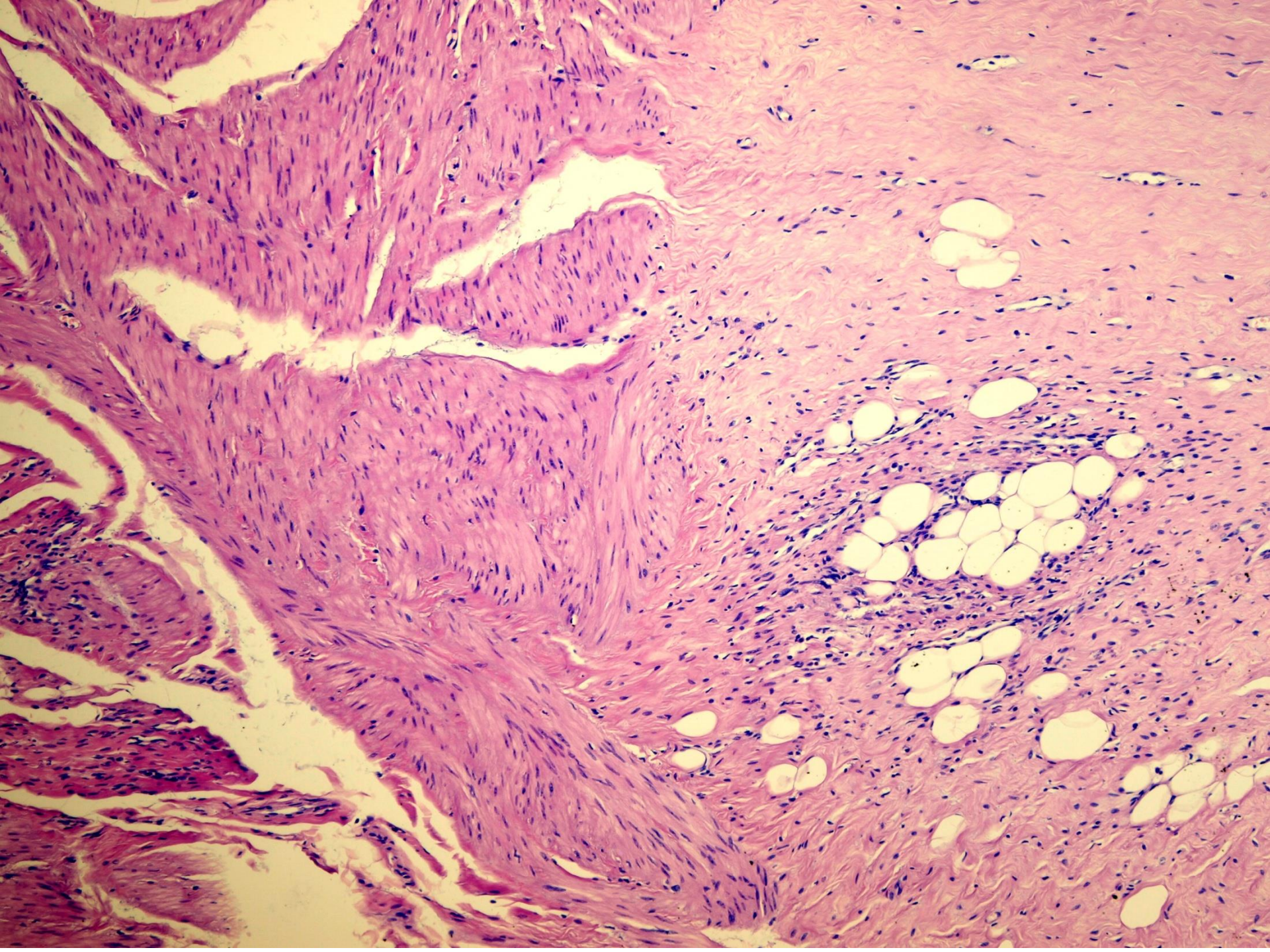


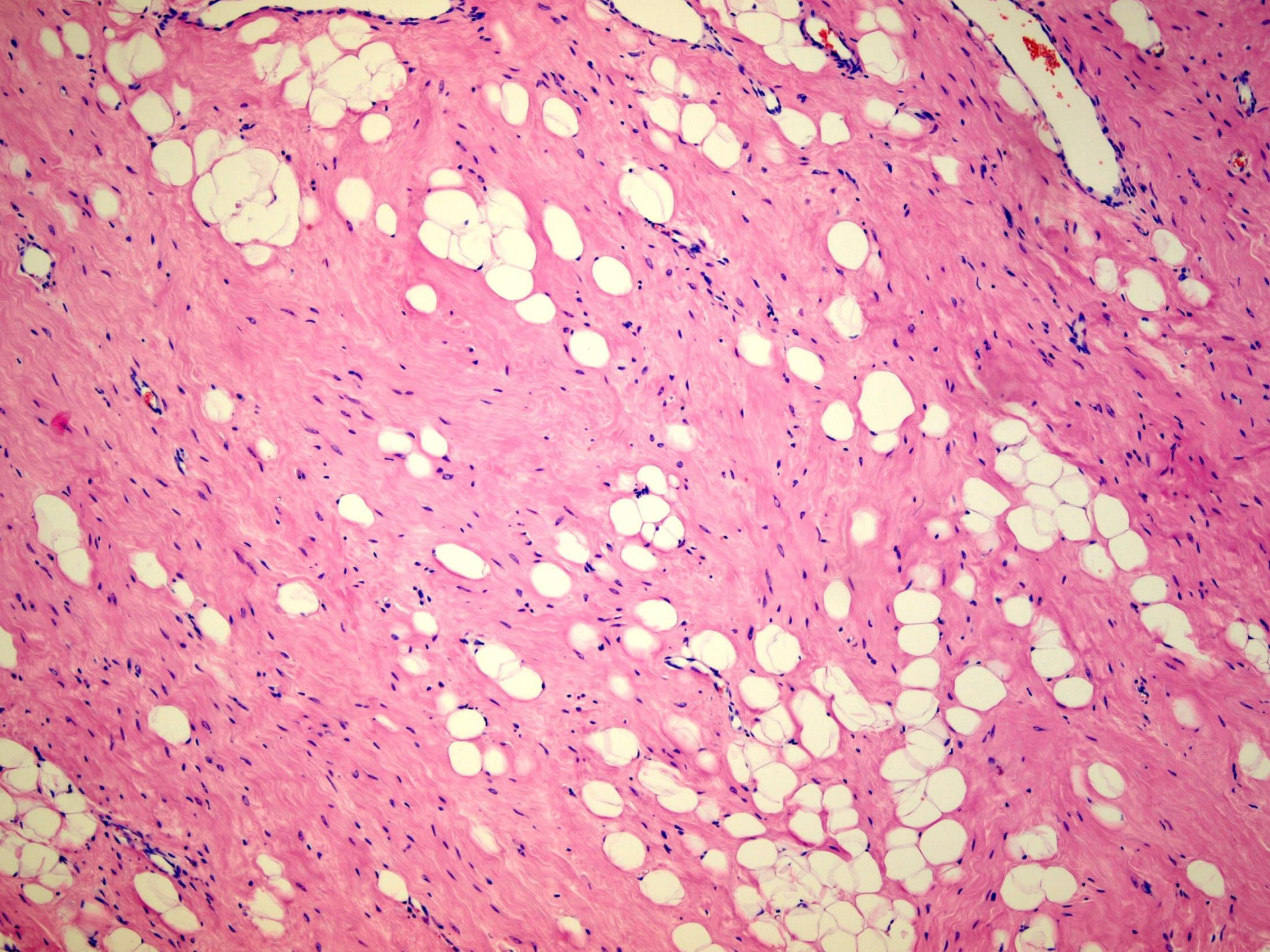
RB

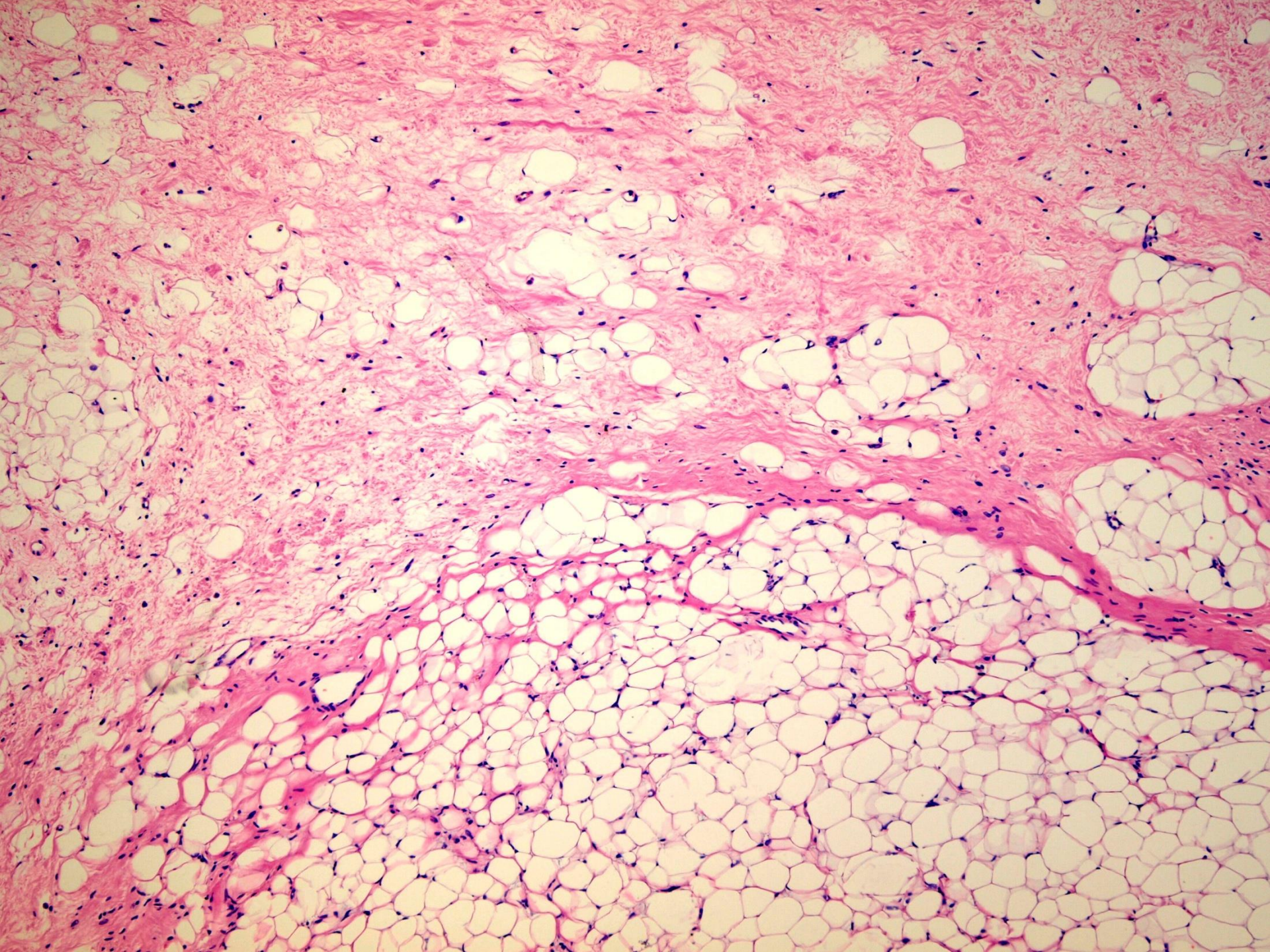
Vretenobunkový tumor s  
extenzívnym lipomatóznym  
komponentom

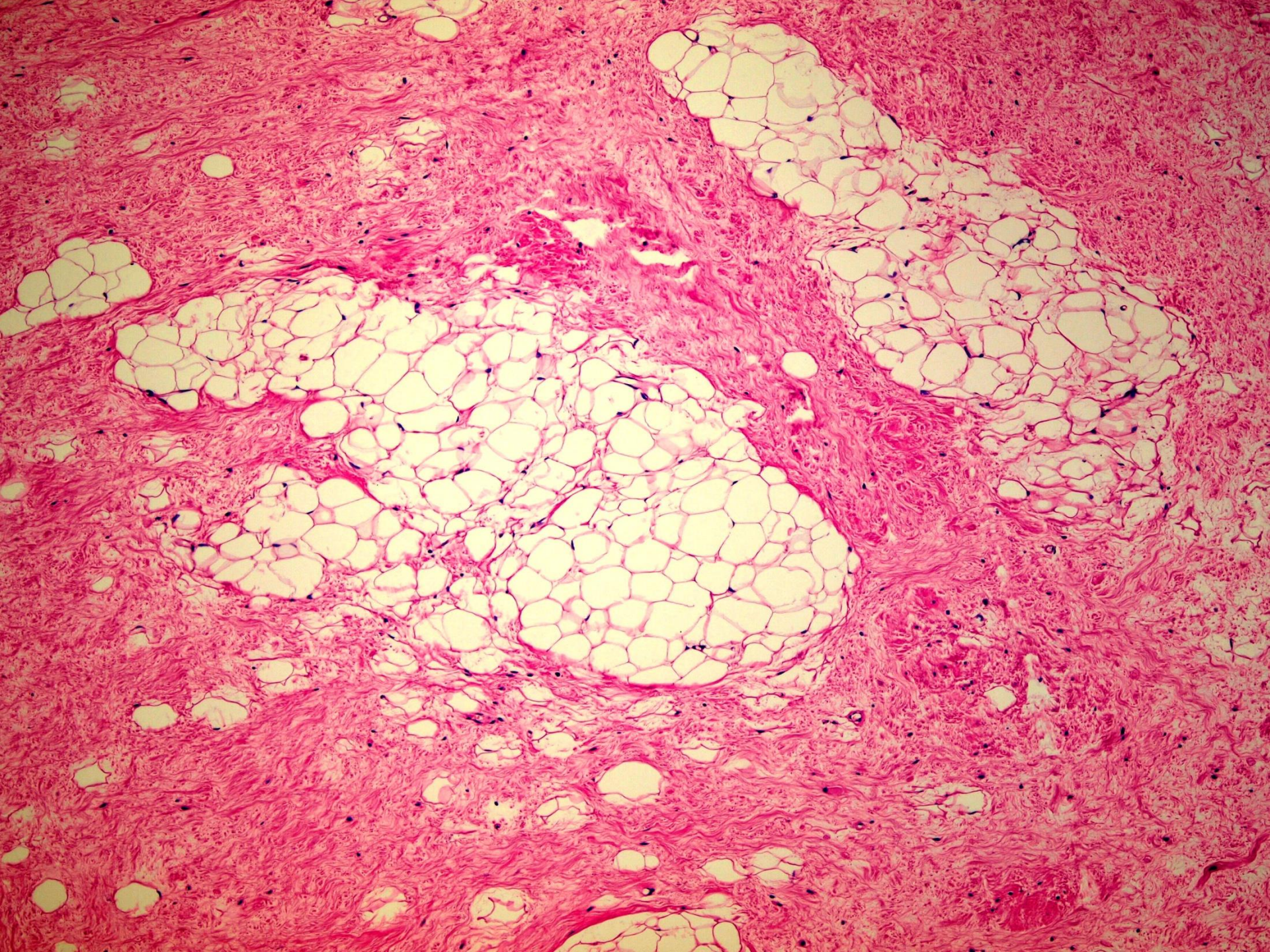
?

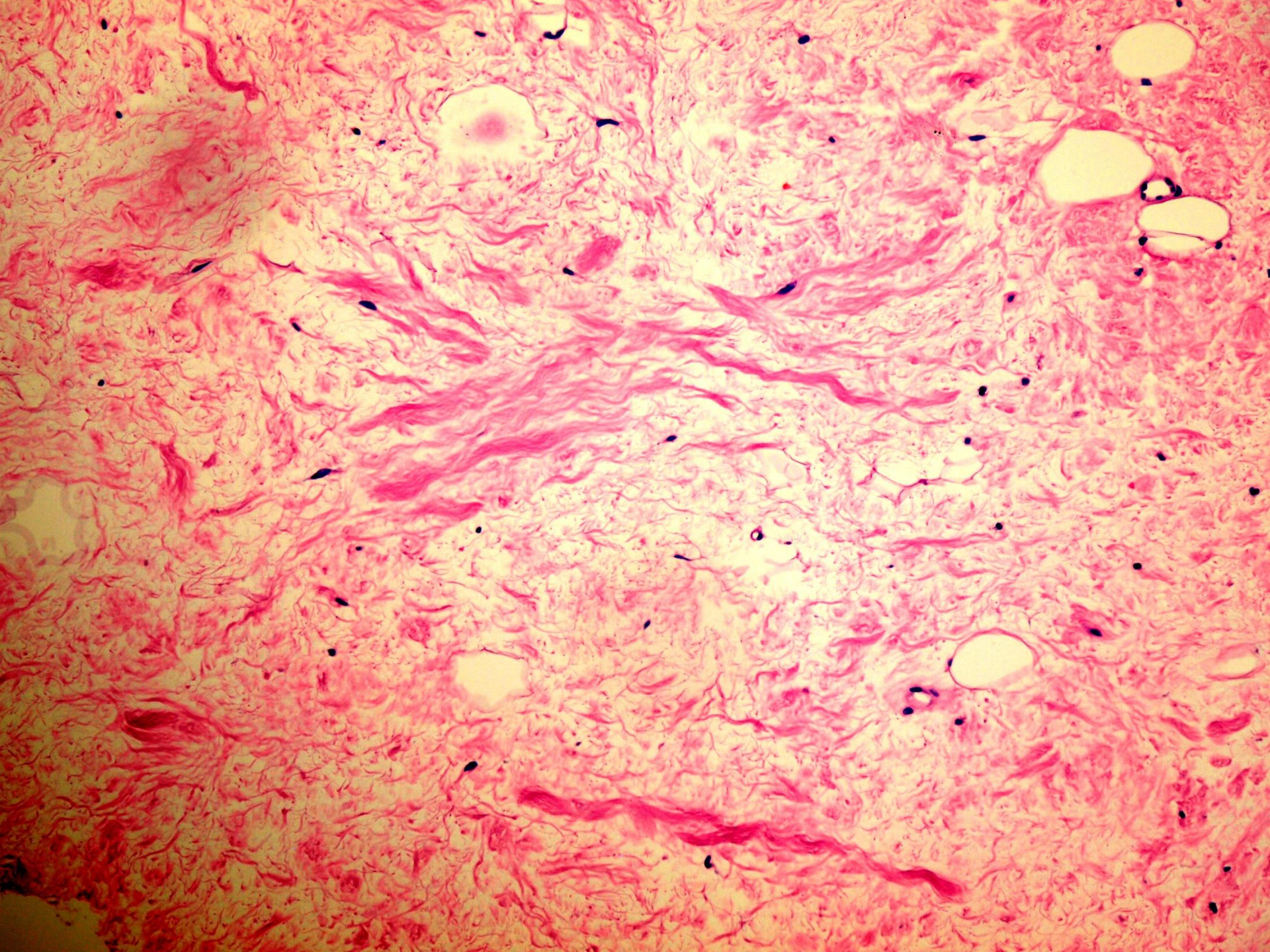


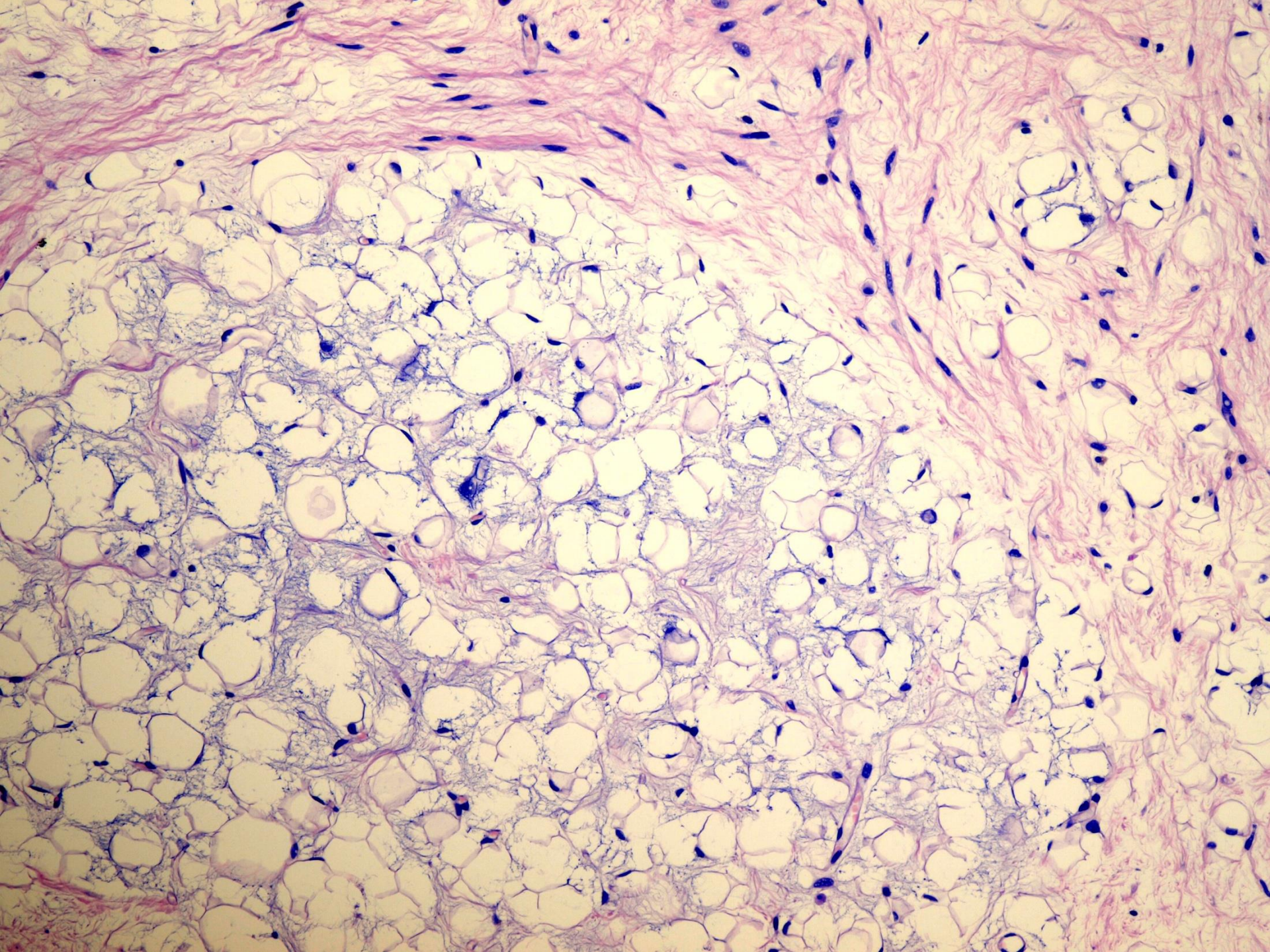




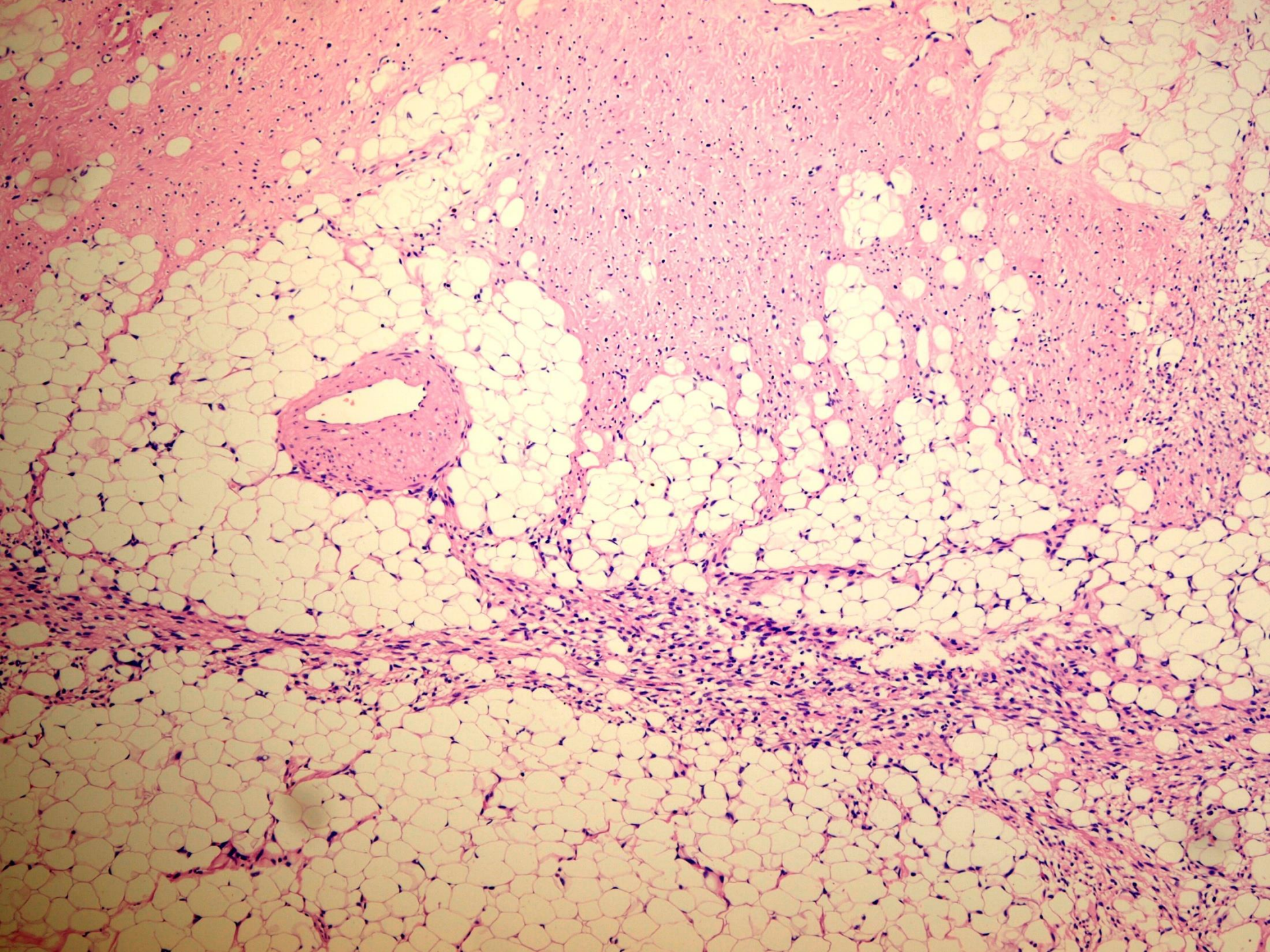


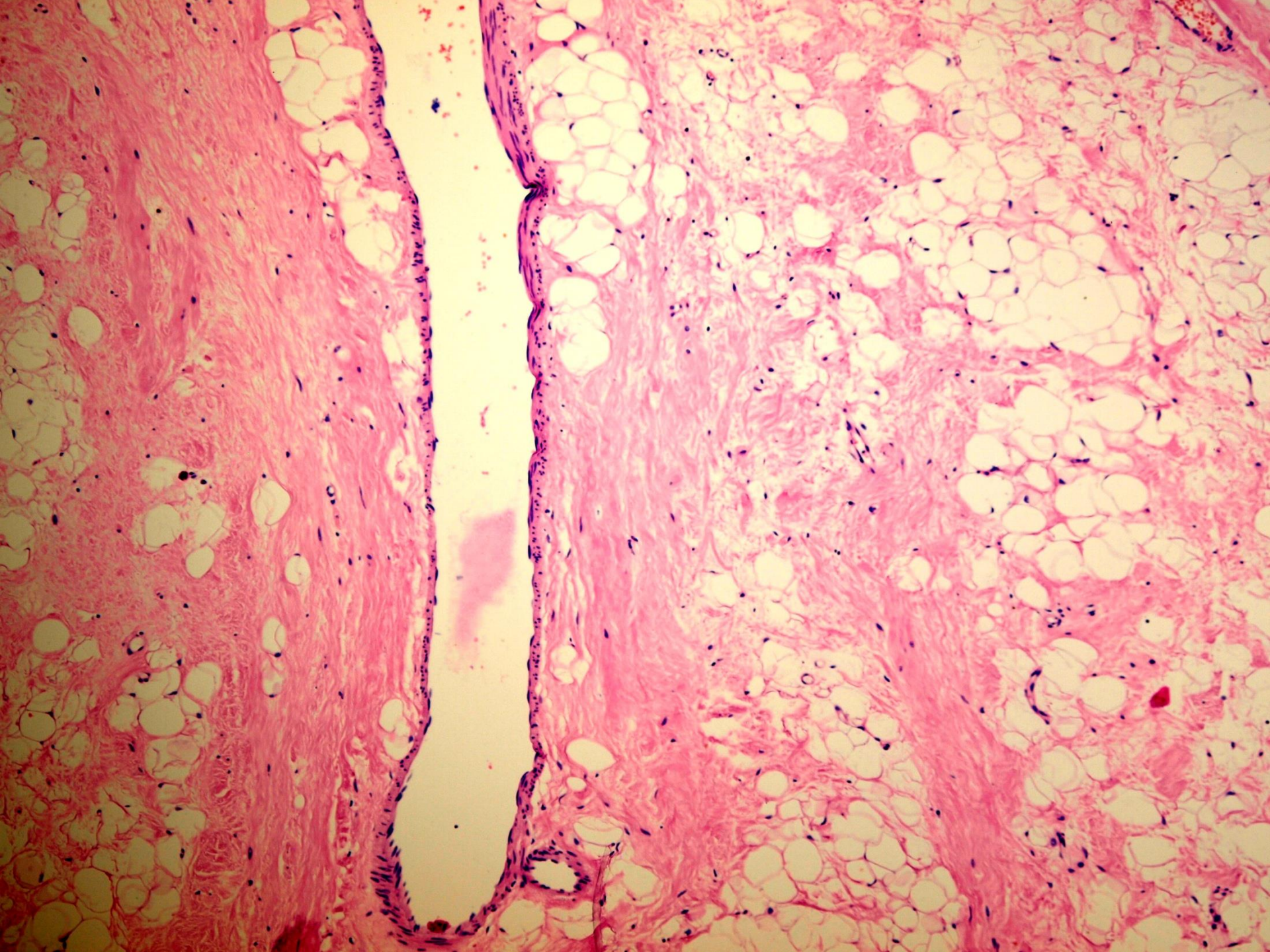


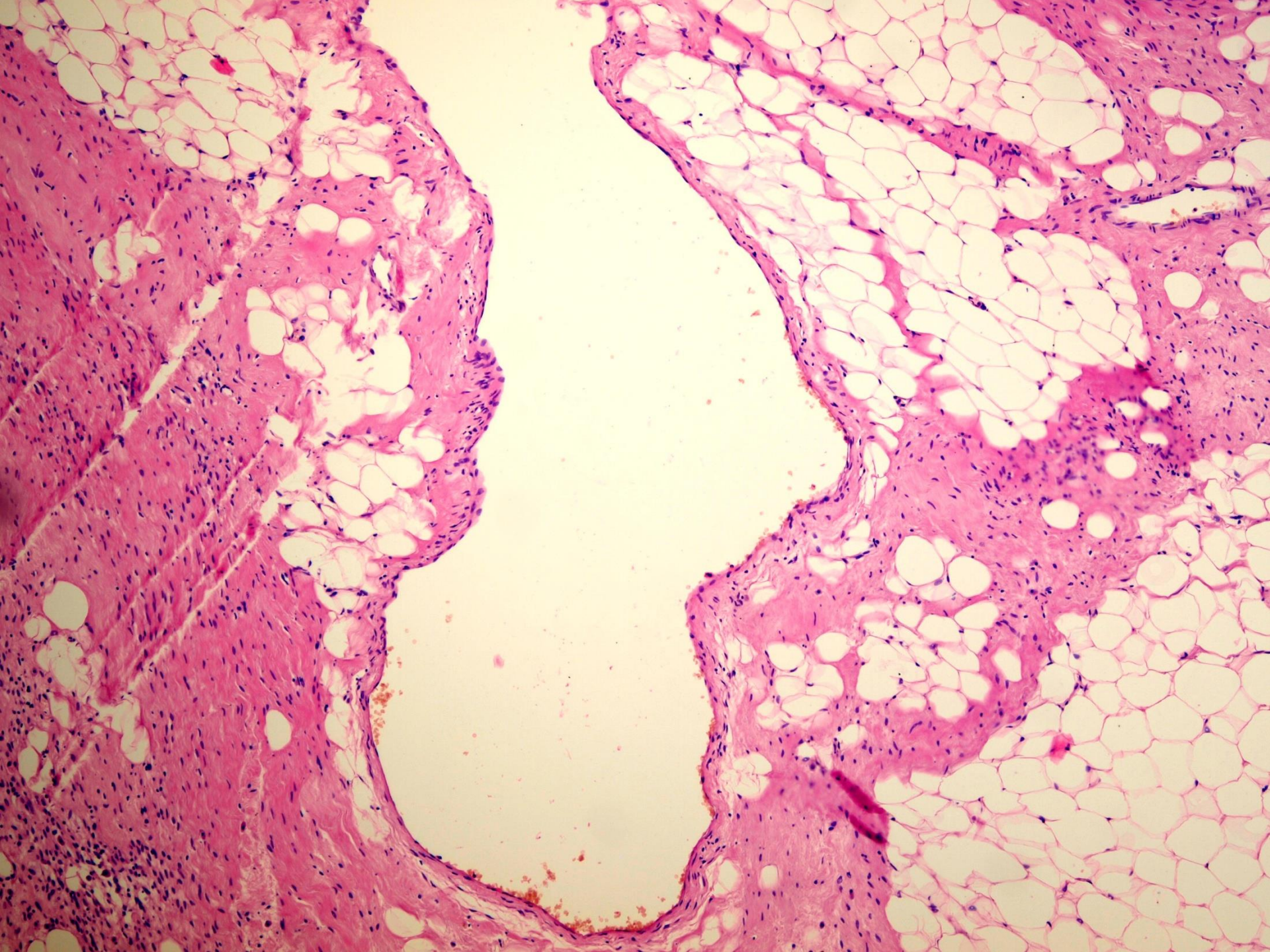


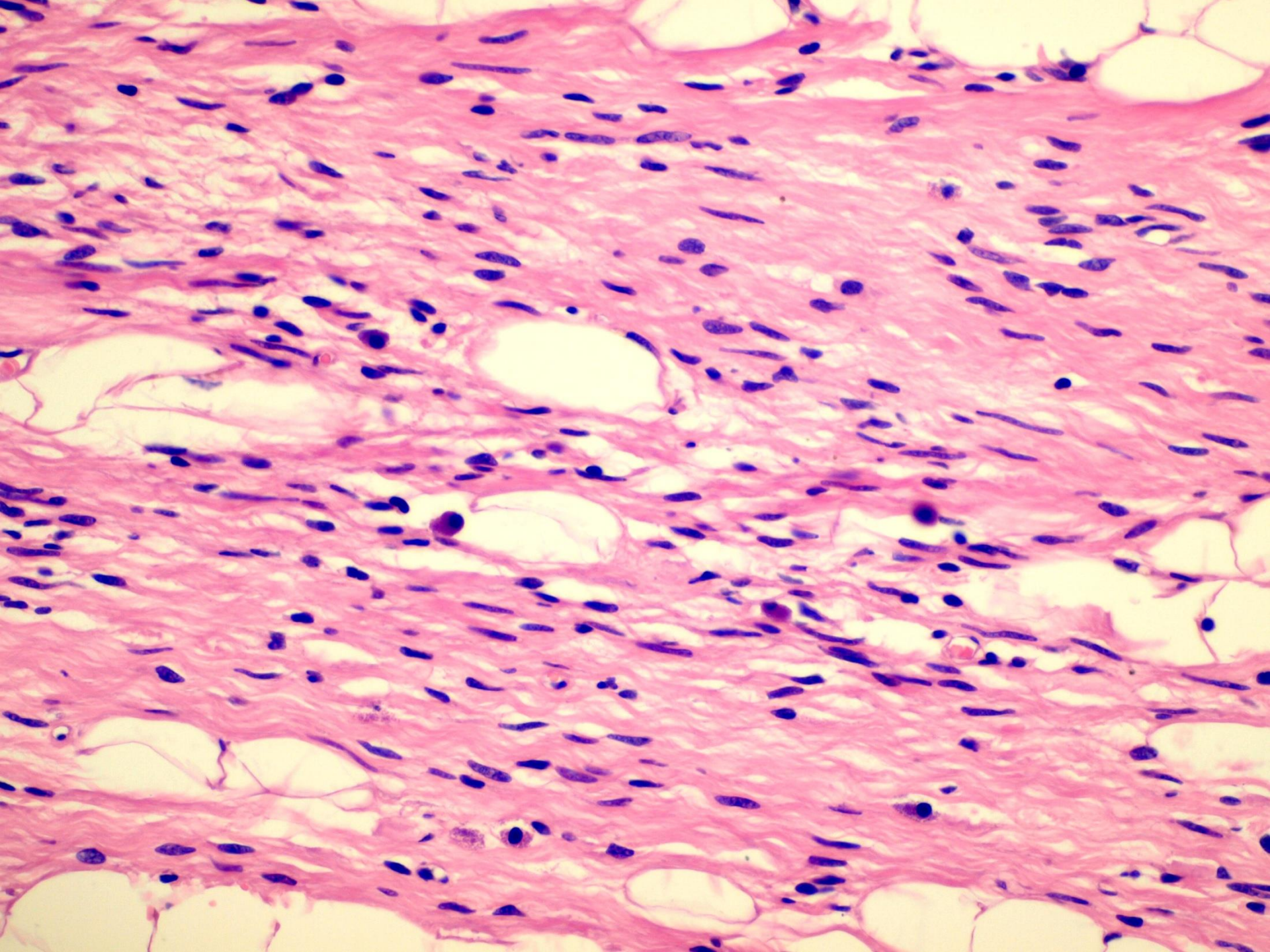


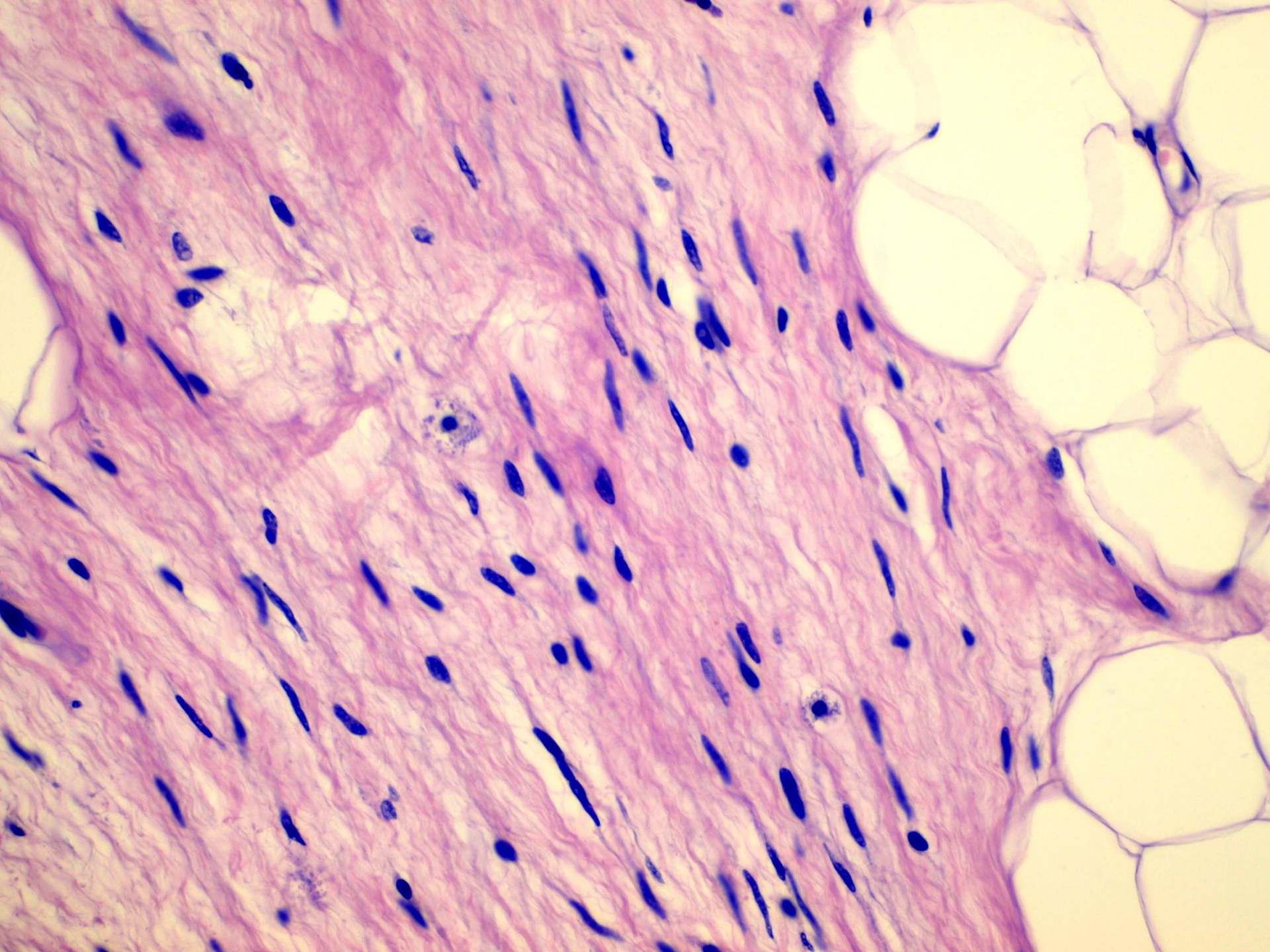


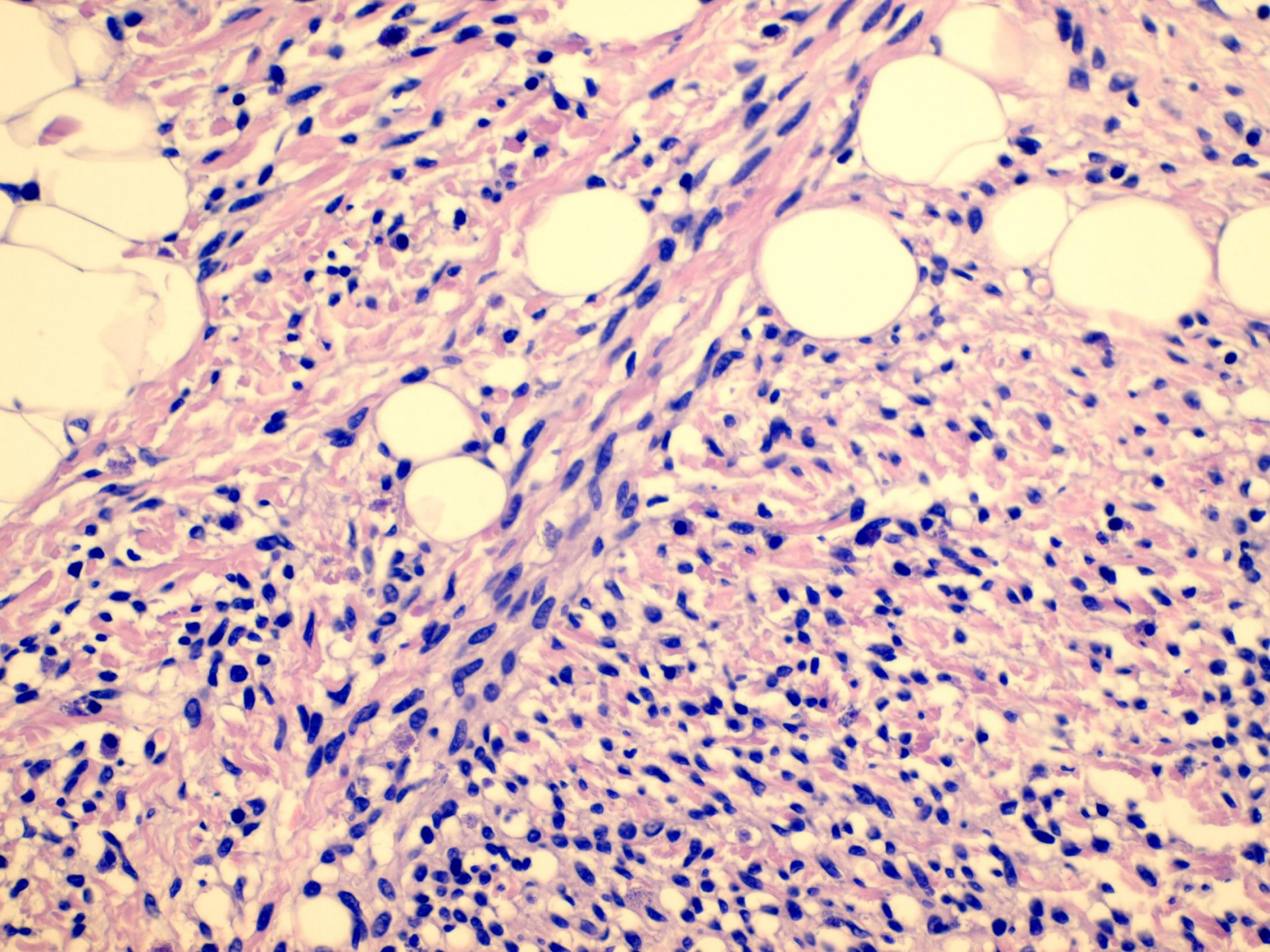


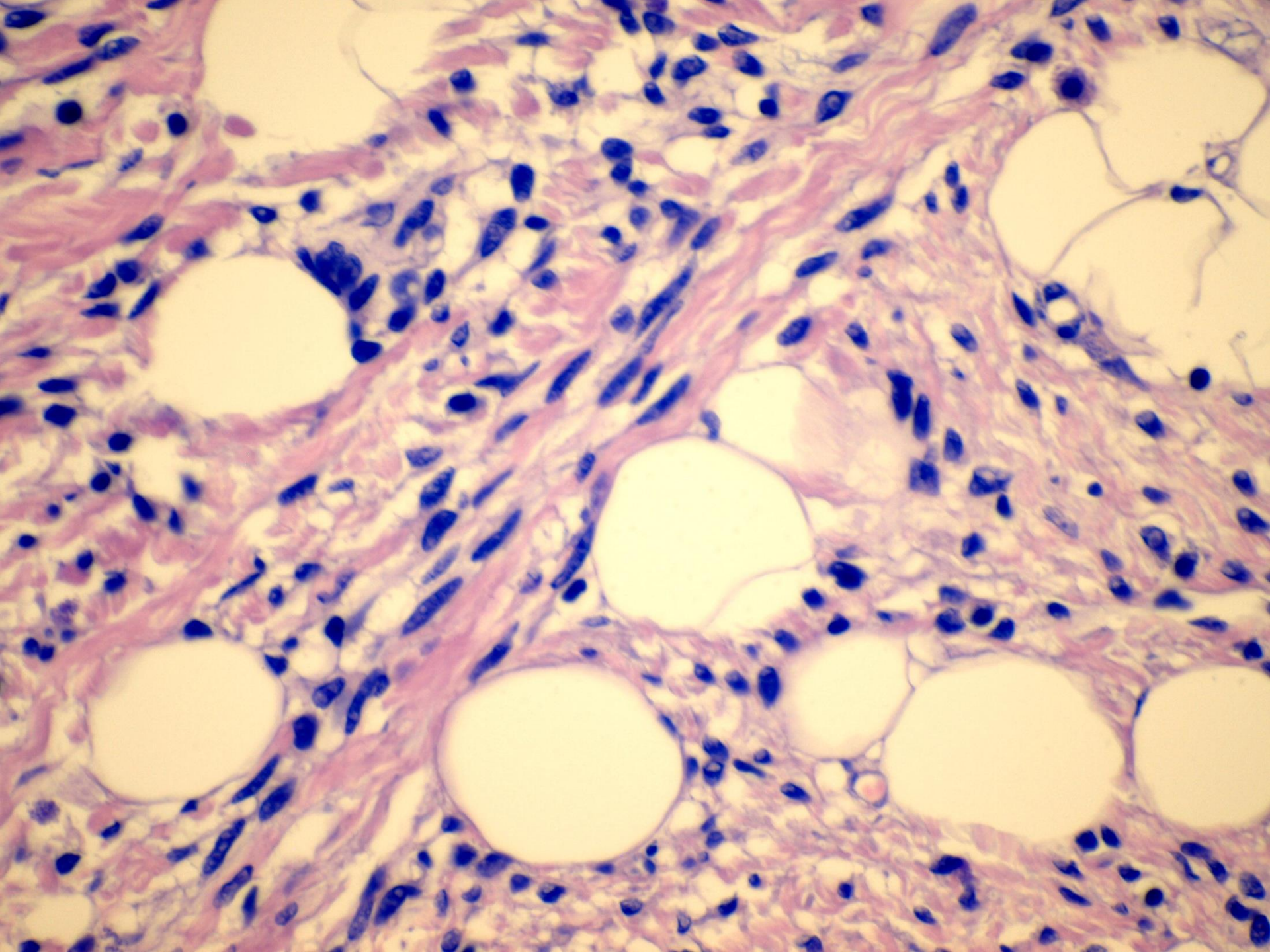


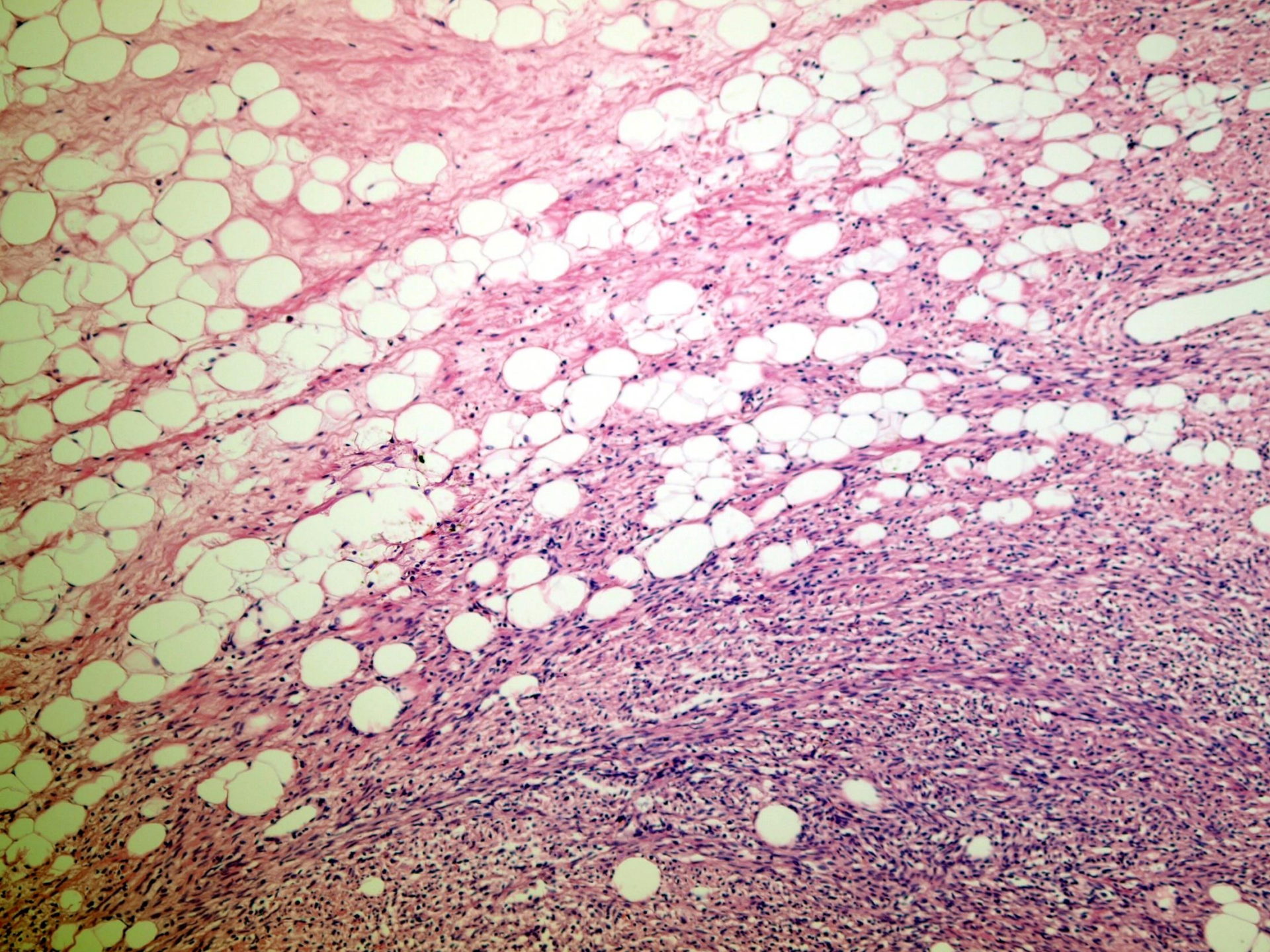




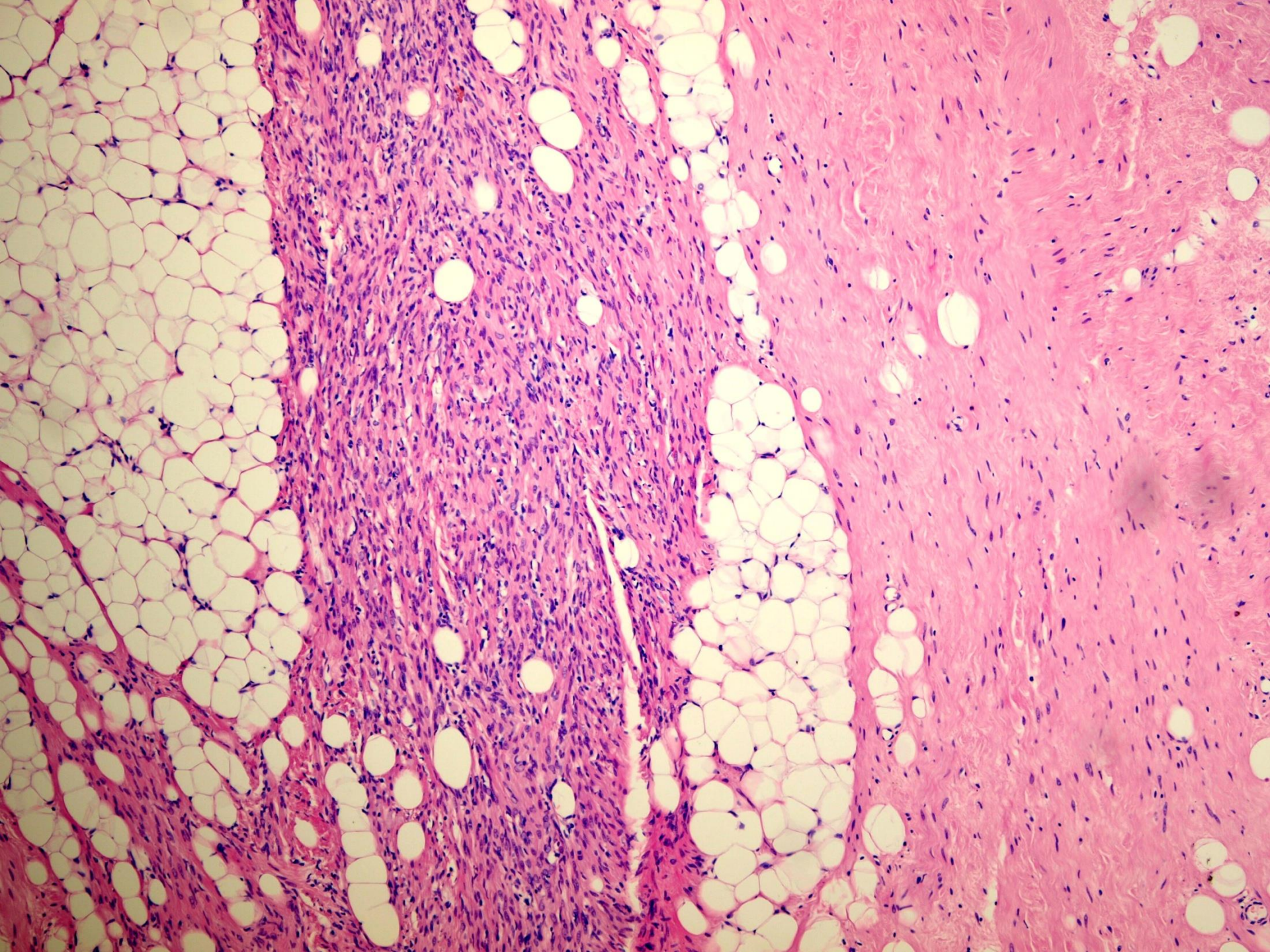


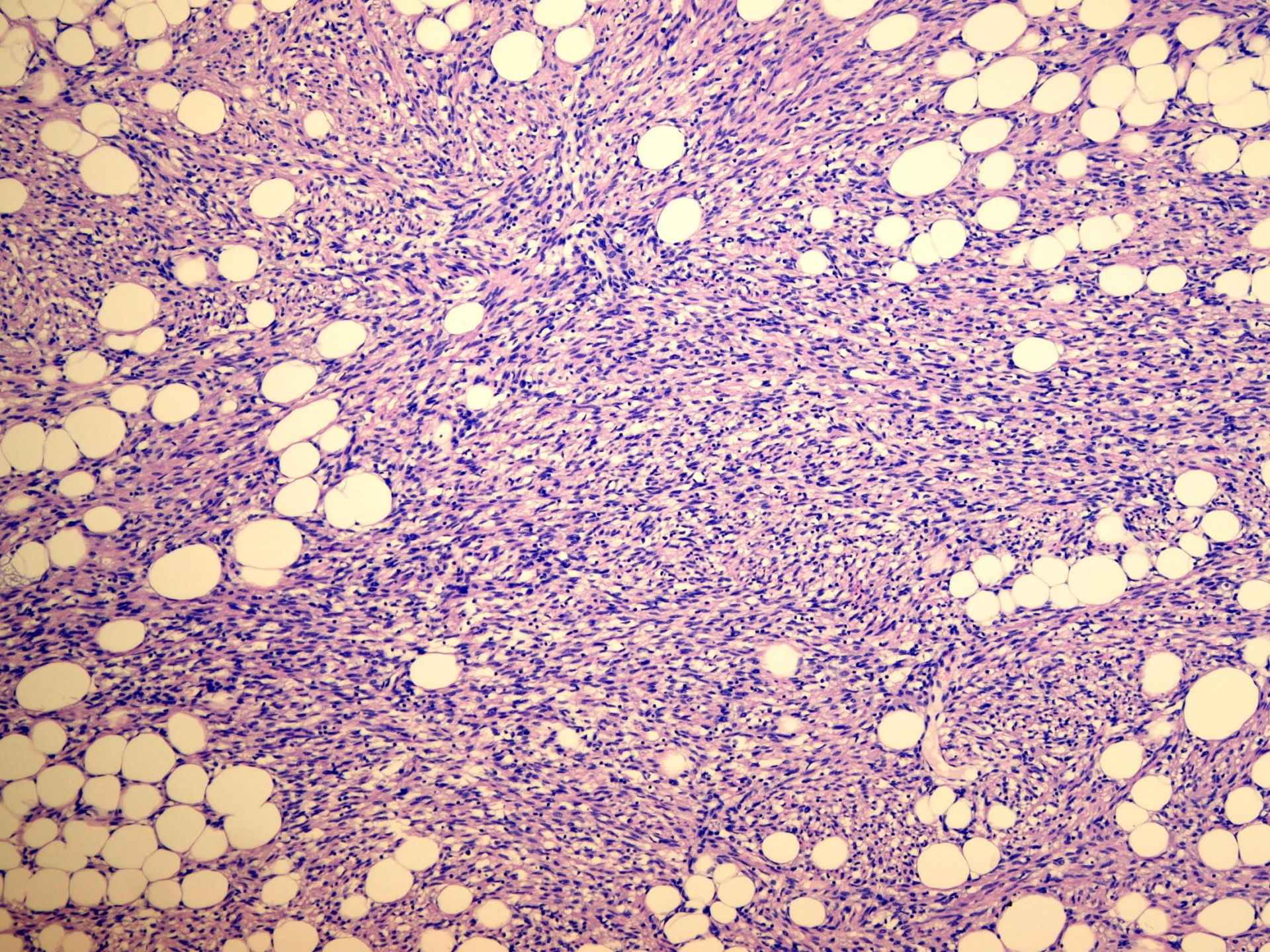


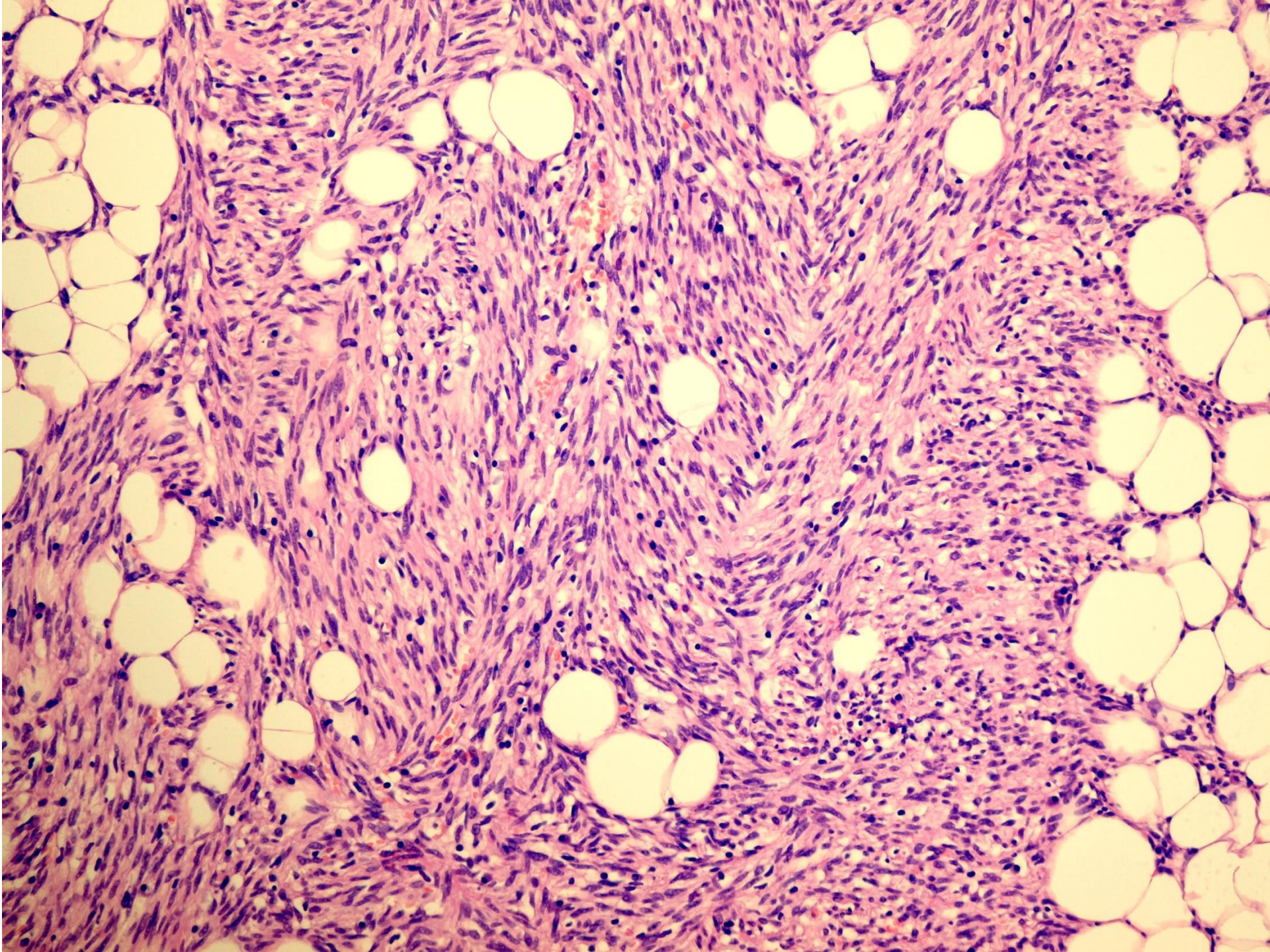


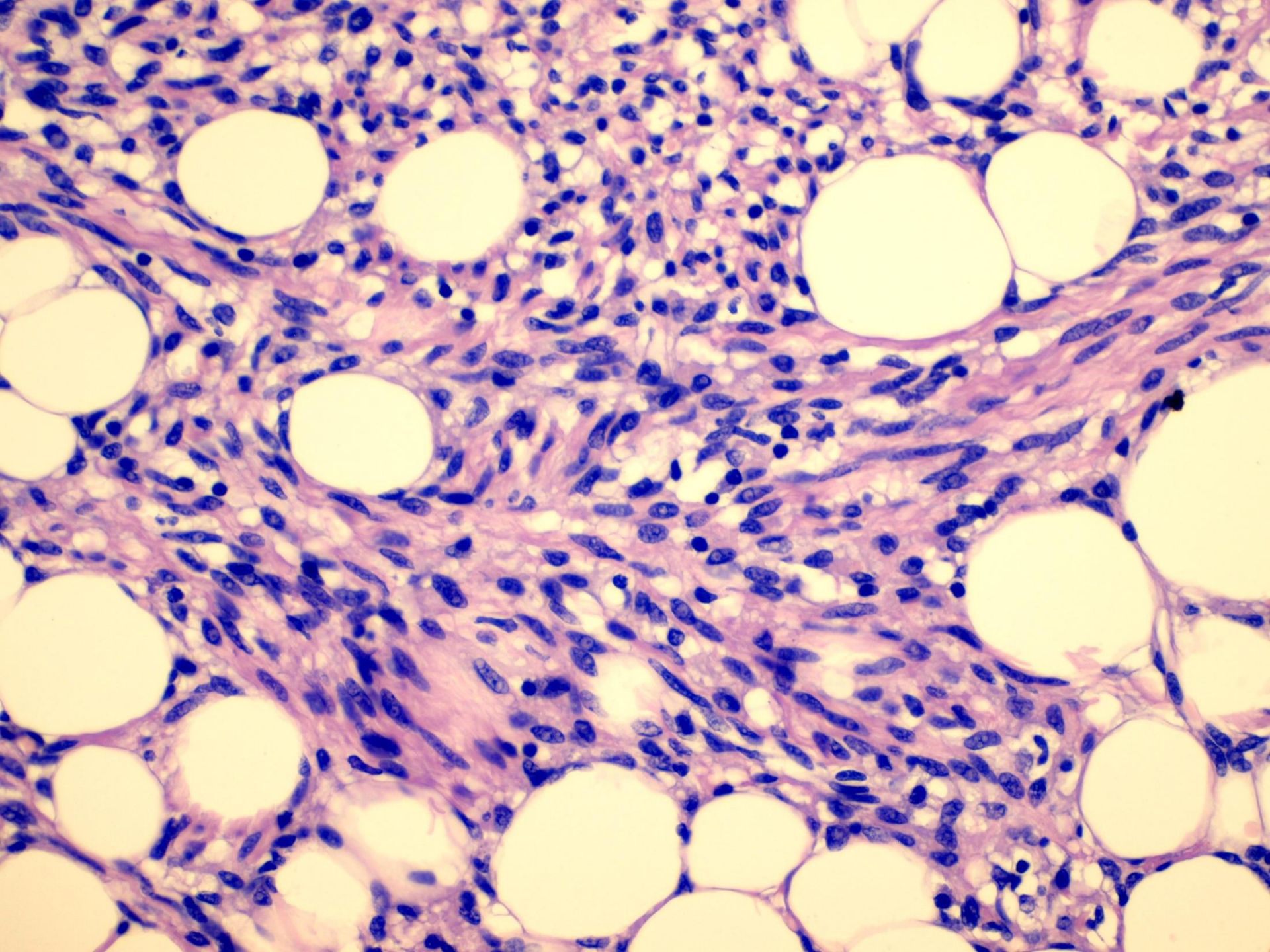


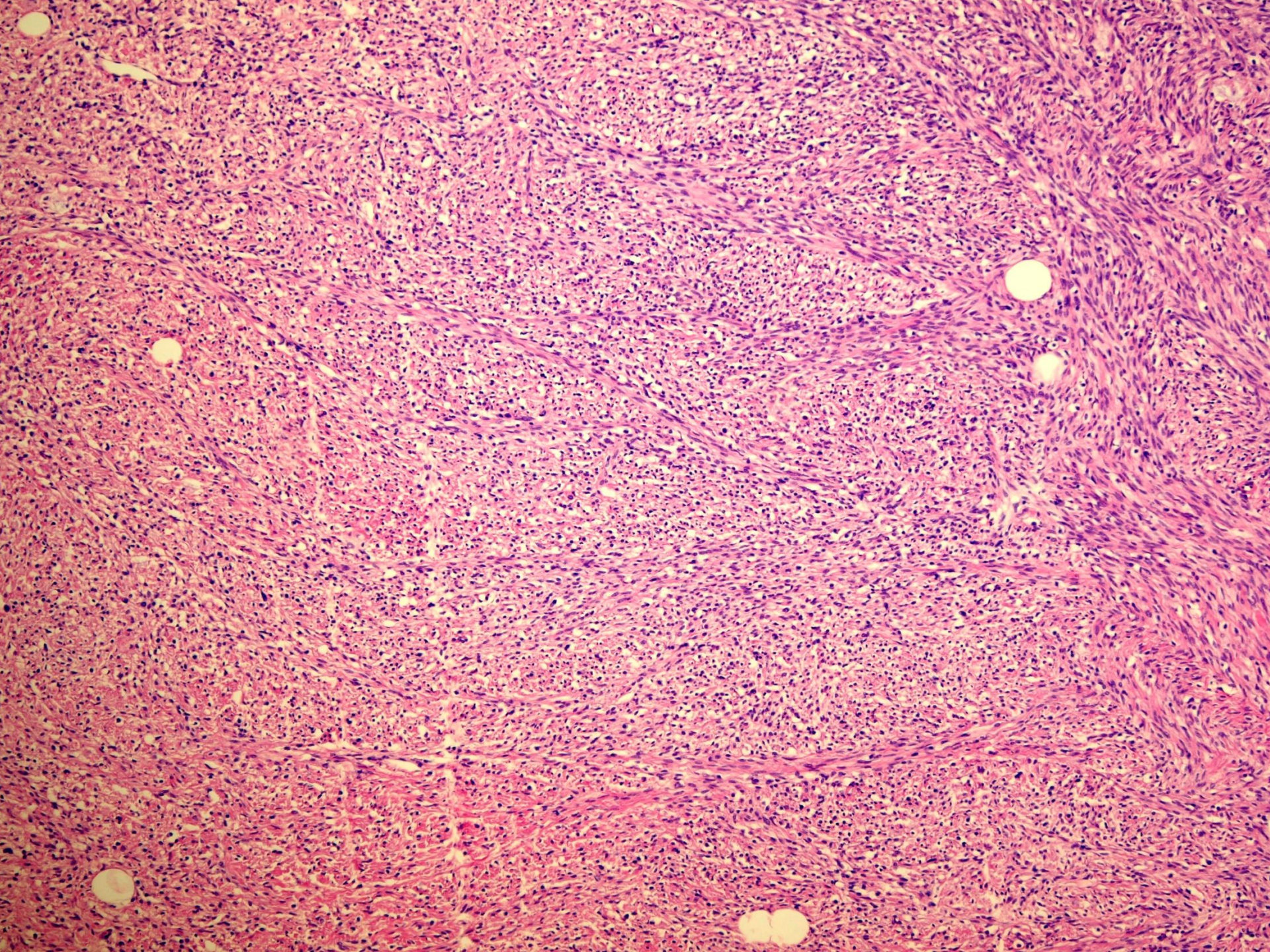


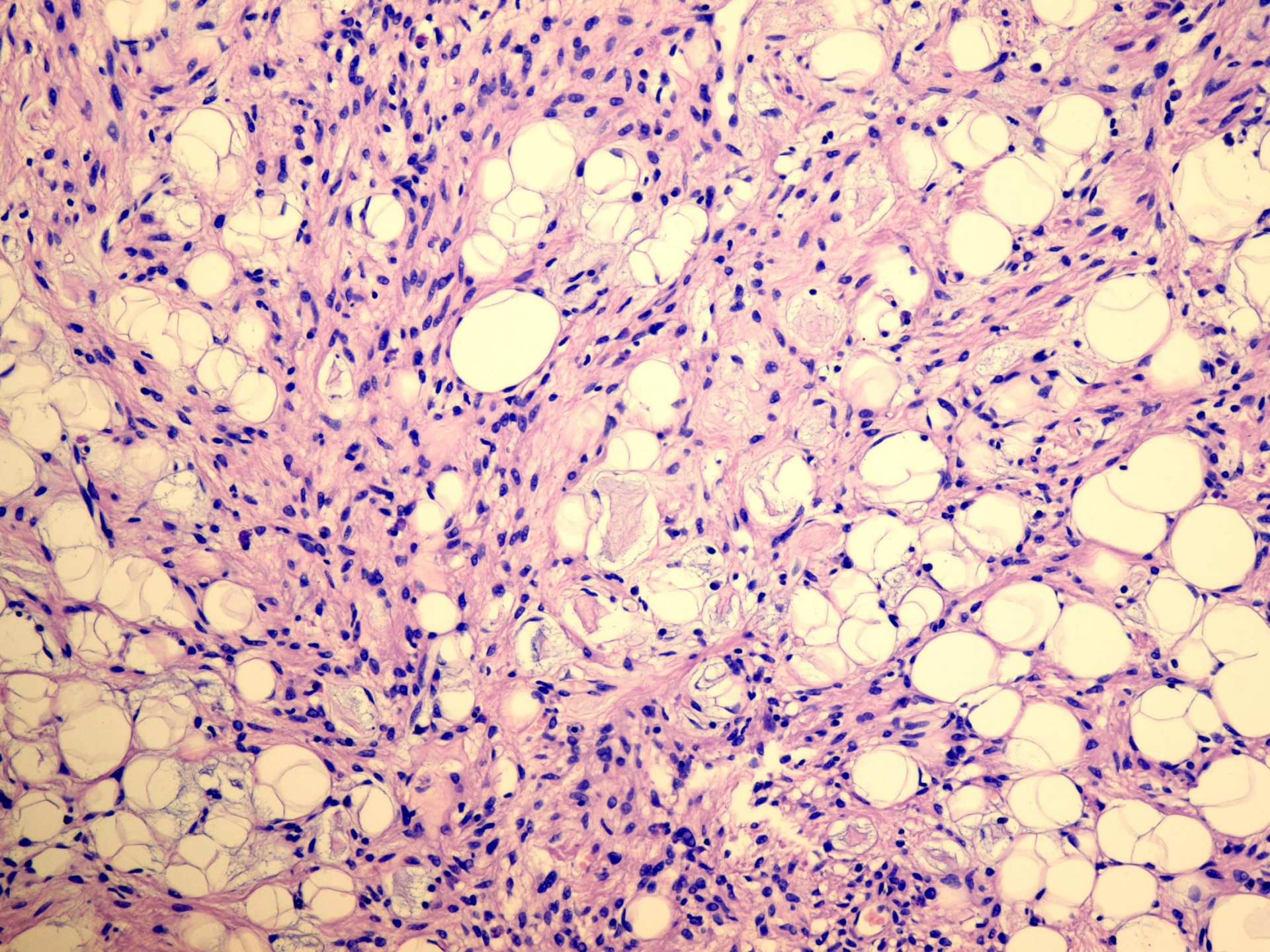


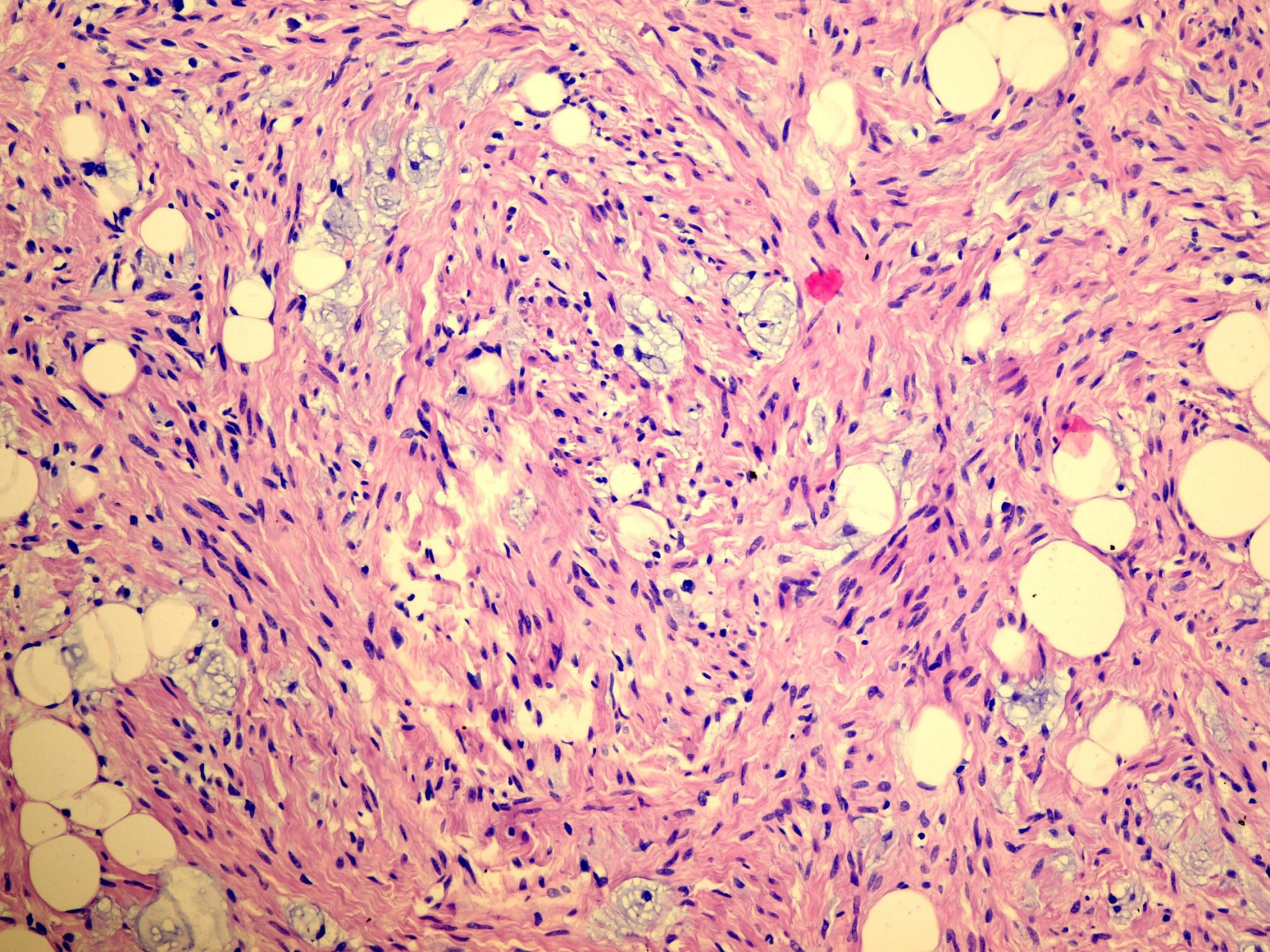


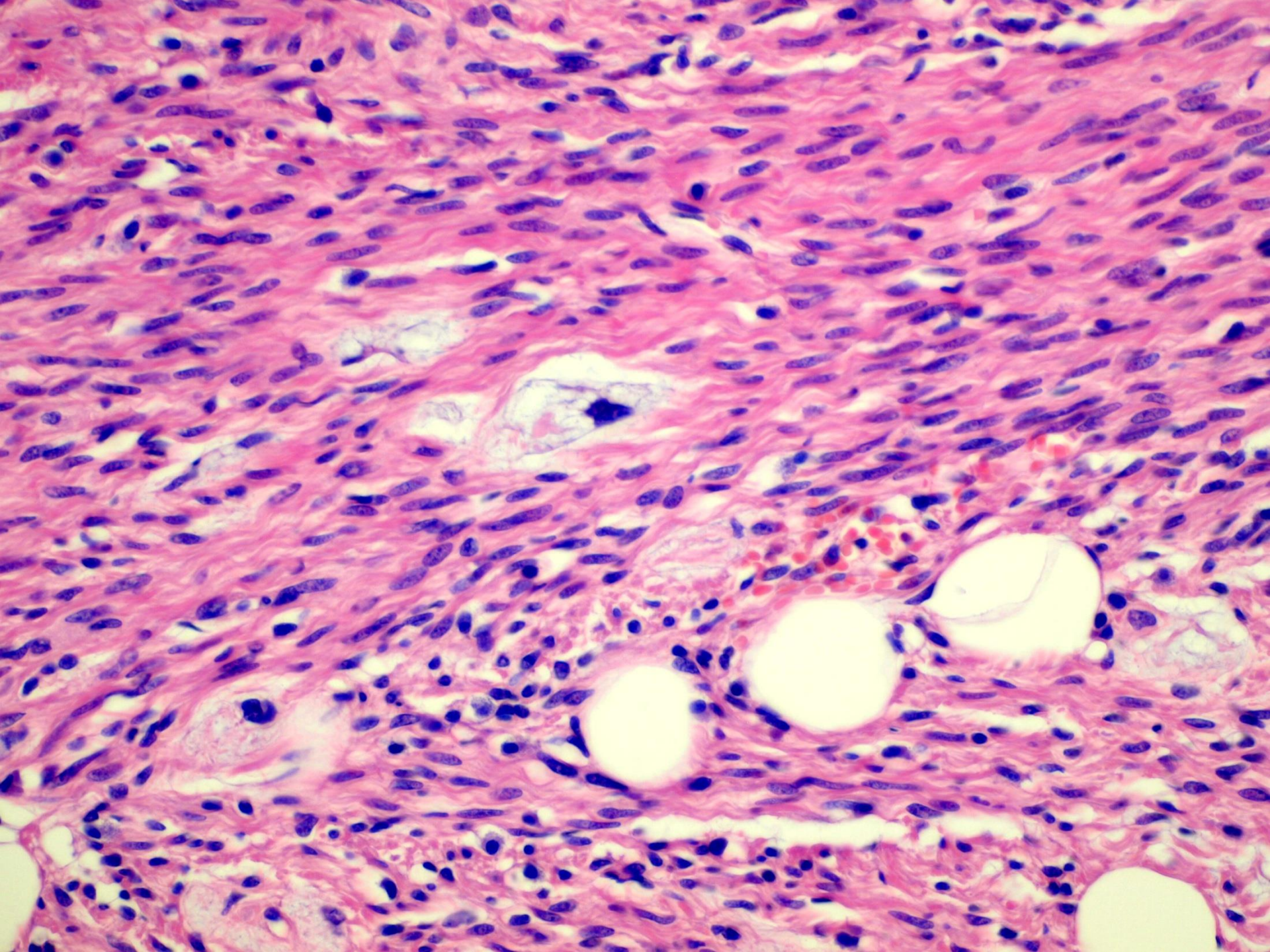




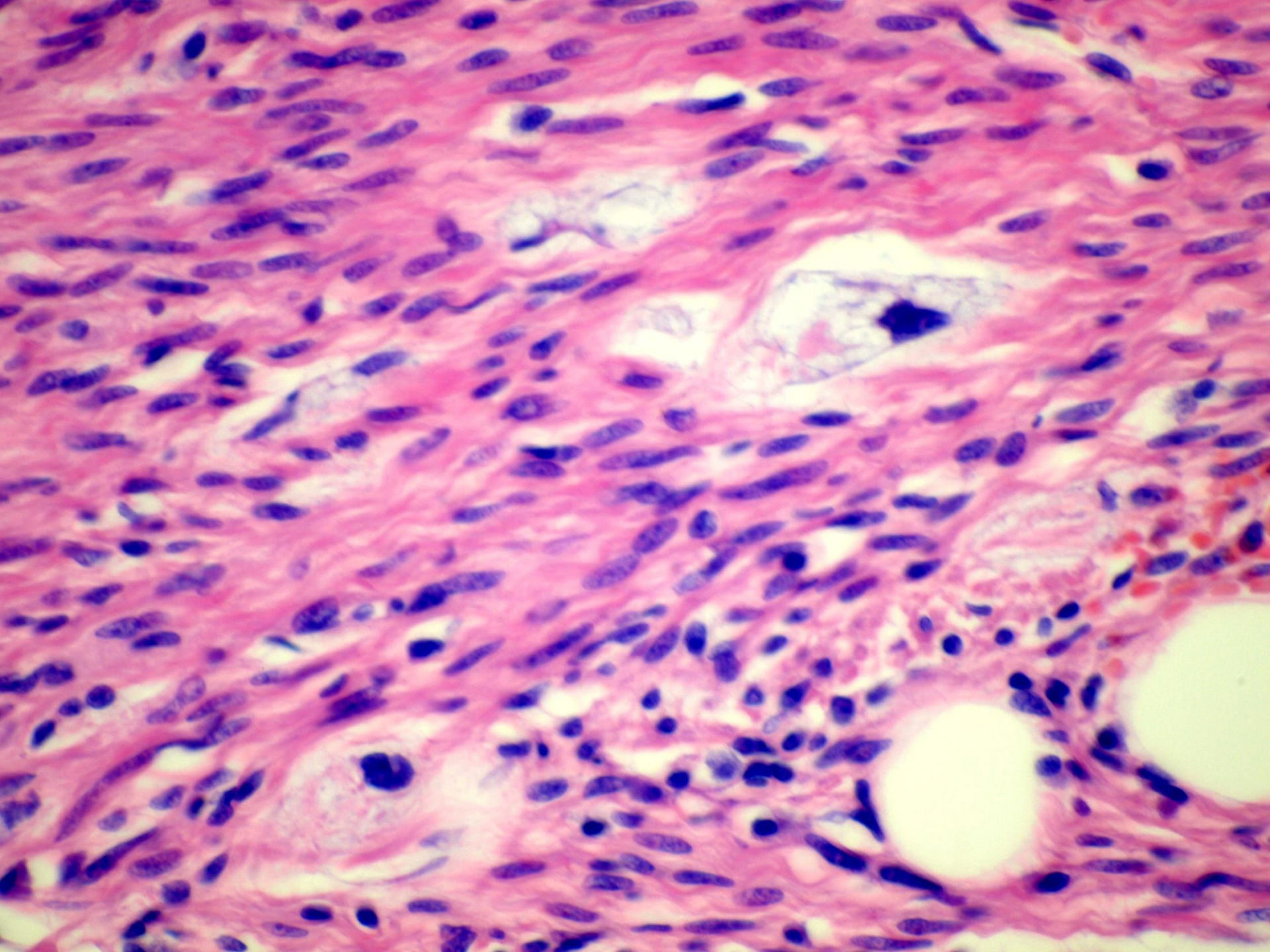


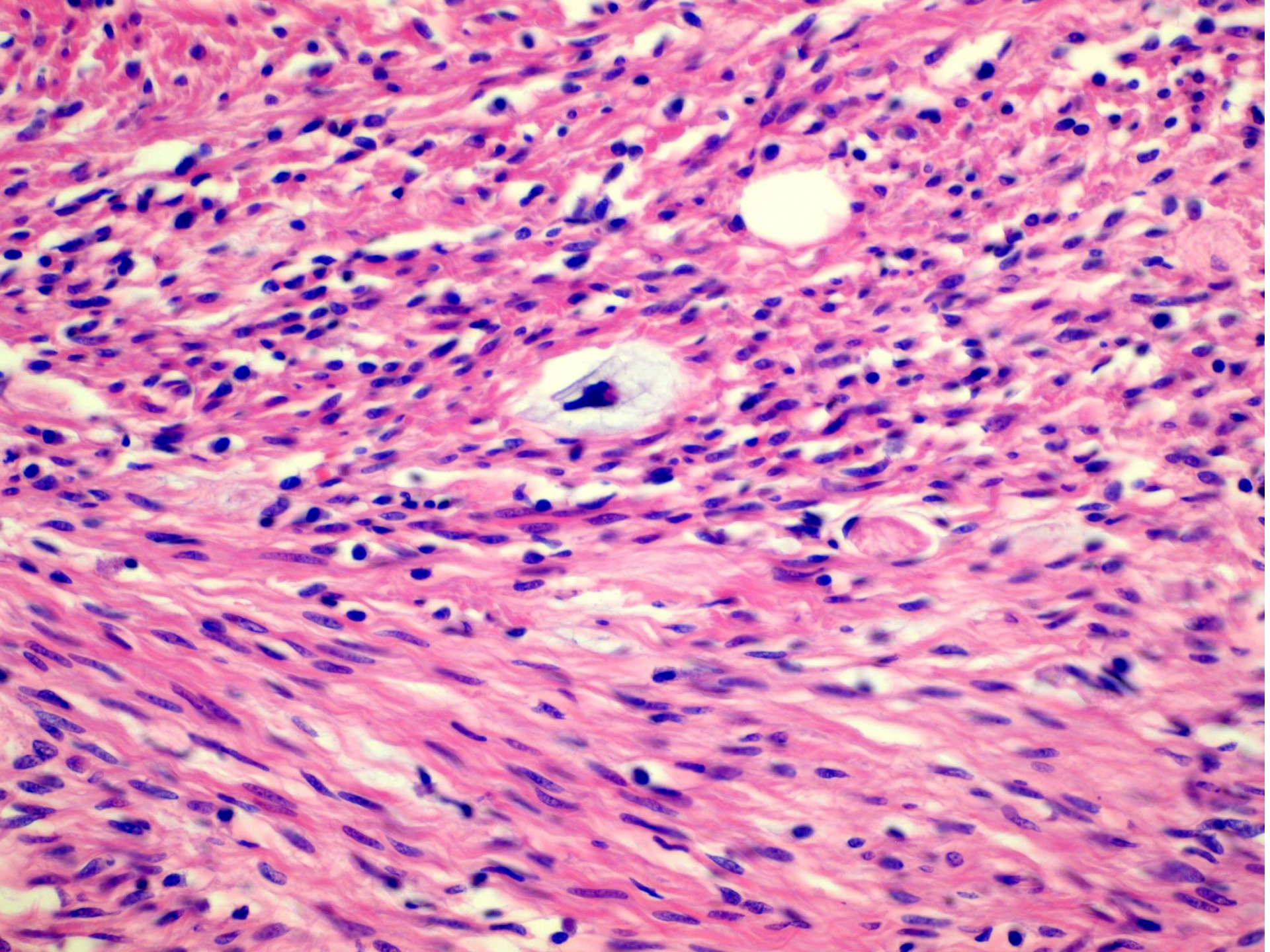






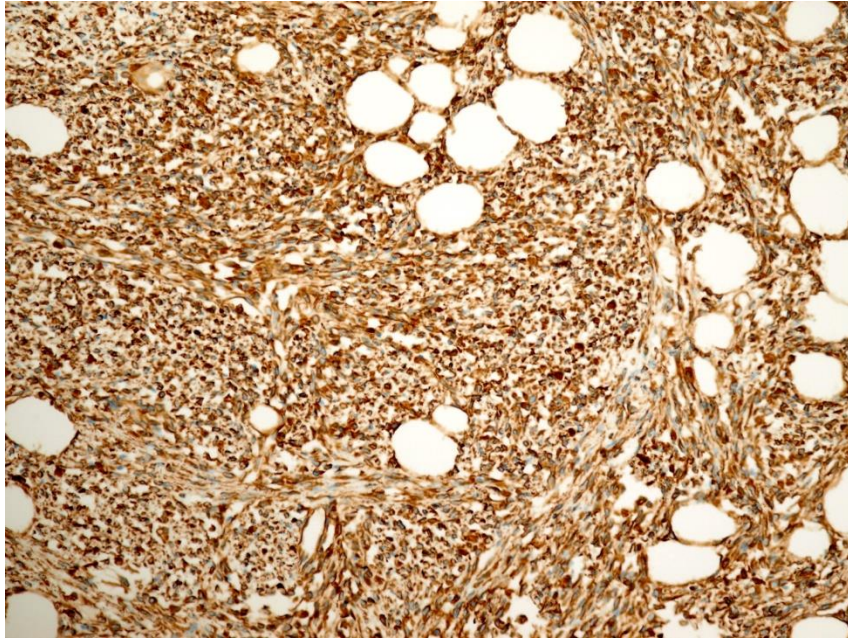




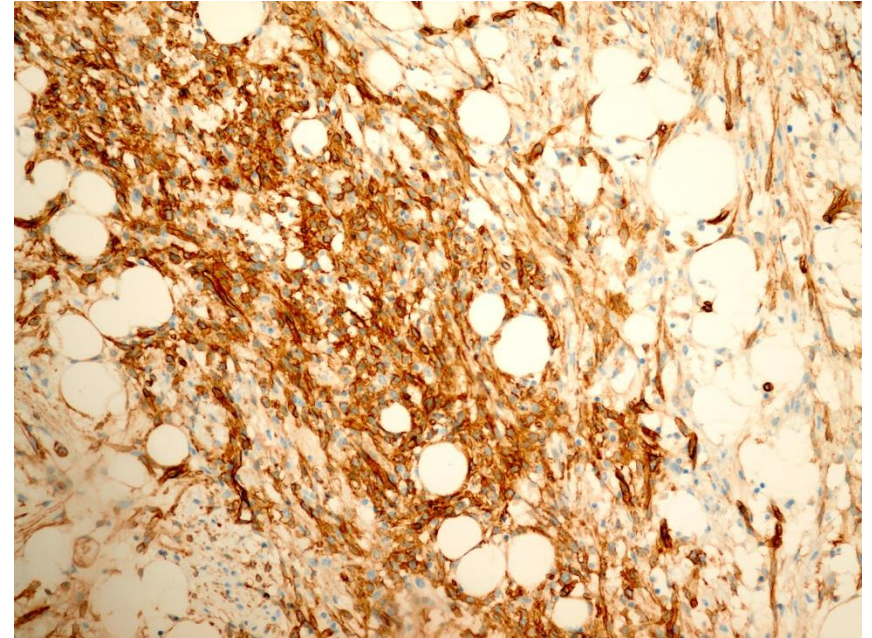




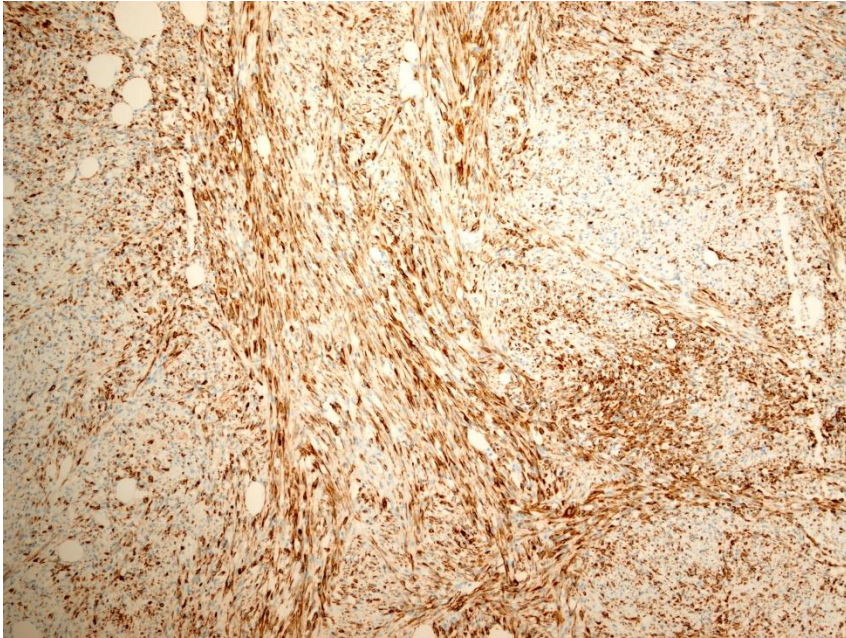
# Vimentin



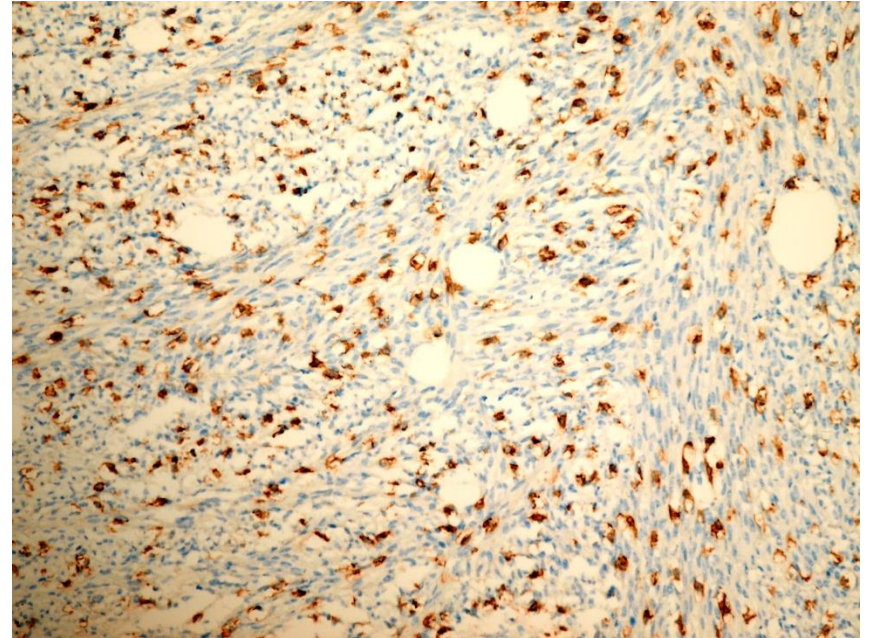
# CD34



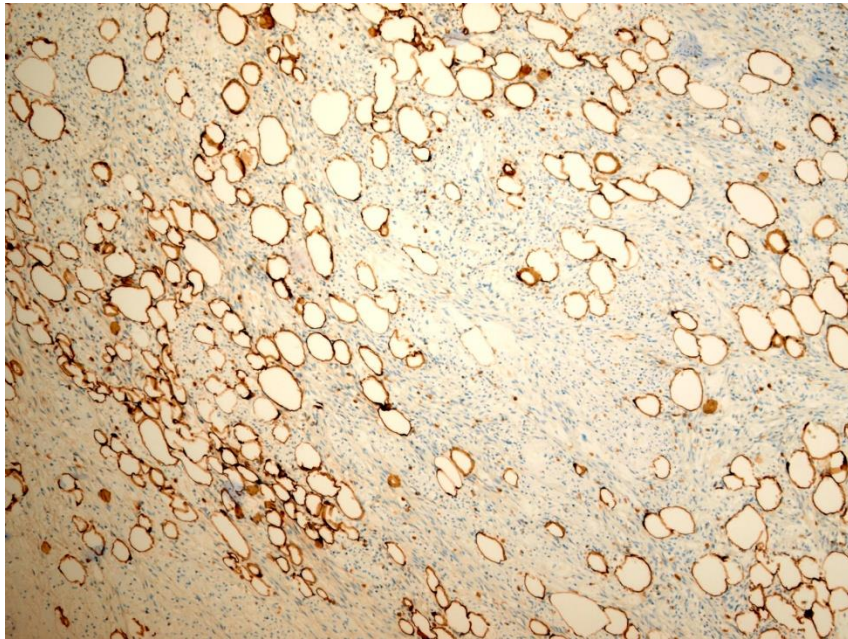
# Desmin



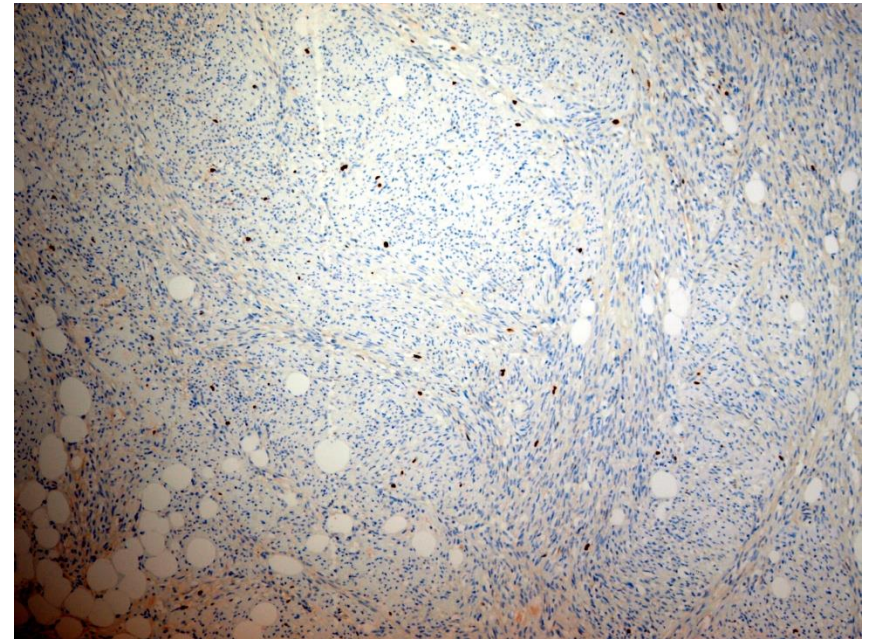
# CD117



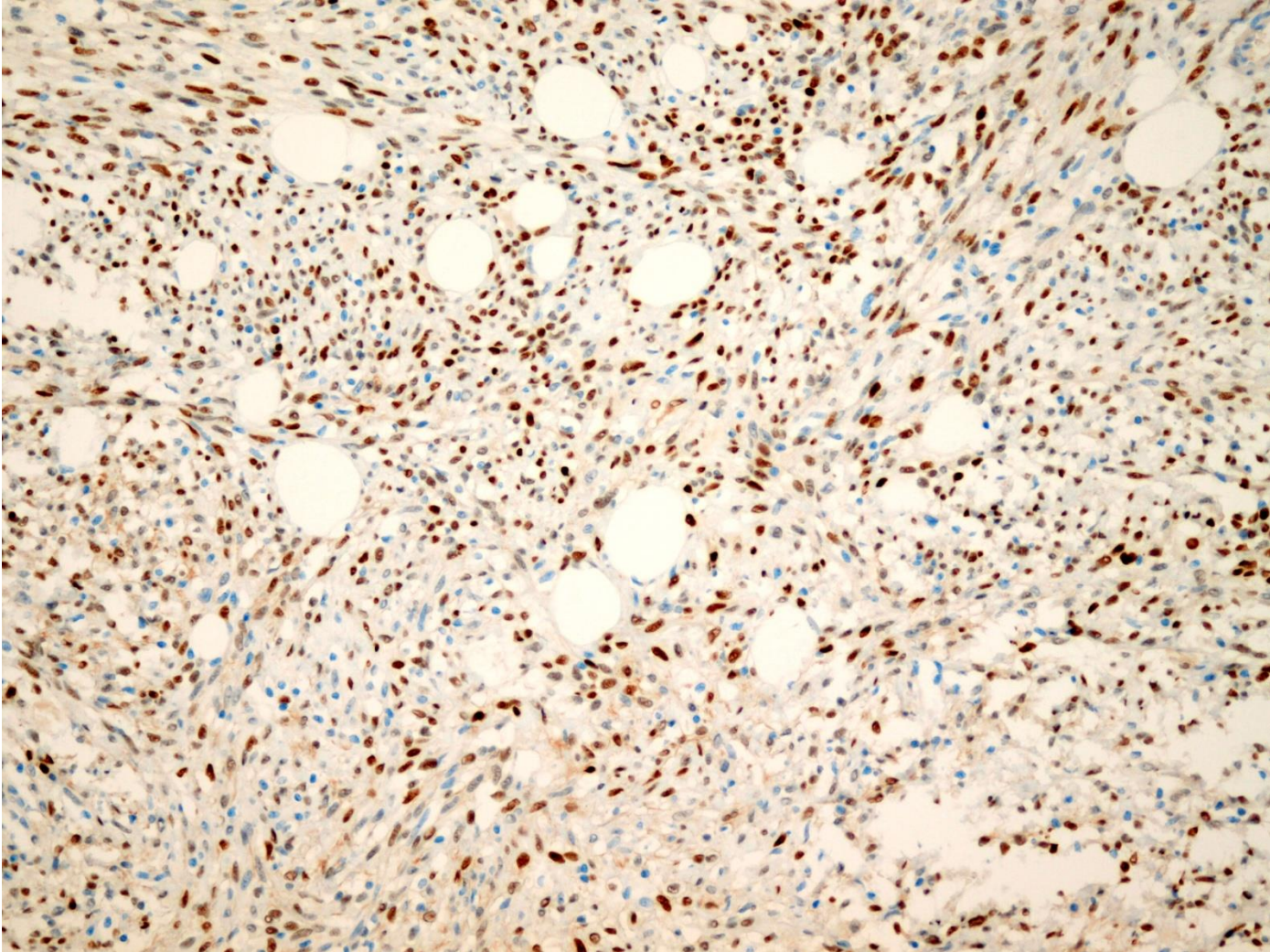
S-100 proteín



Ki-67



ER







**Lipomatous mammary-  
type myofibroblastoma  
(MTMF)**

# 13q/Rb rodina nádorov

delécia alebo preskupenie

13q14

# MTMF

- Wargotz a spol. (1987)
- prsná žľaza starších mužov
- McMenamin, Fletcher (2001) - séria extramamárnych MTMF
- variabilná anatomická distribúcia
- morfológická heterogenita
- diagnostika v prsníku jednoduchá

ORIGINAL ARTICLE

---

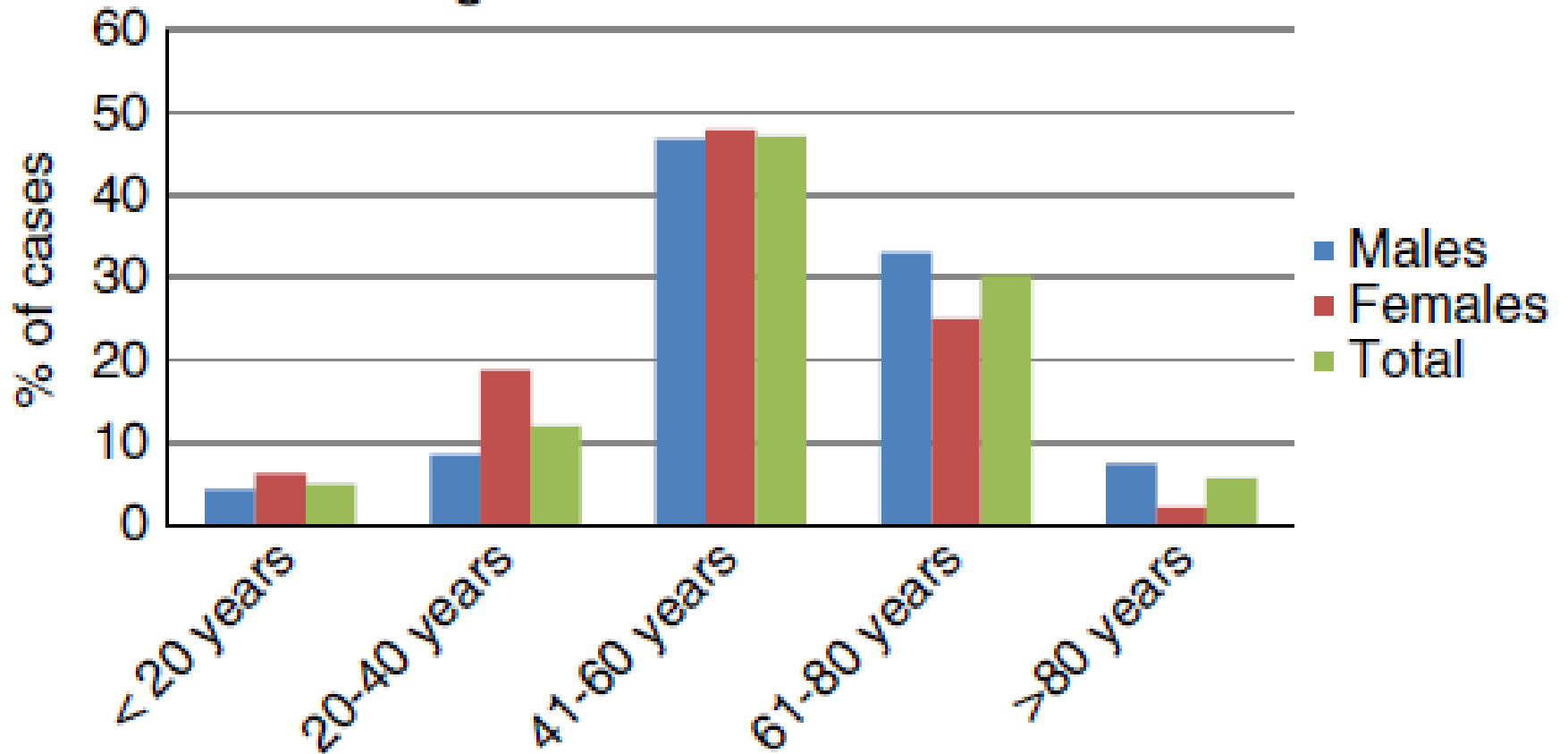
Mammary-type Myofibroblastoma  
*Clinicopathologic Characterization in a Series of 143 Cases*

*Brooke E. Howitt, MD and Christopher D.M. Fletcher, MD, FRCPath*

*(Am J Surg Pathol 2016;40:361–367)*

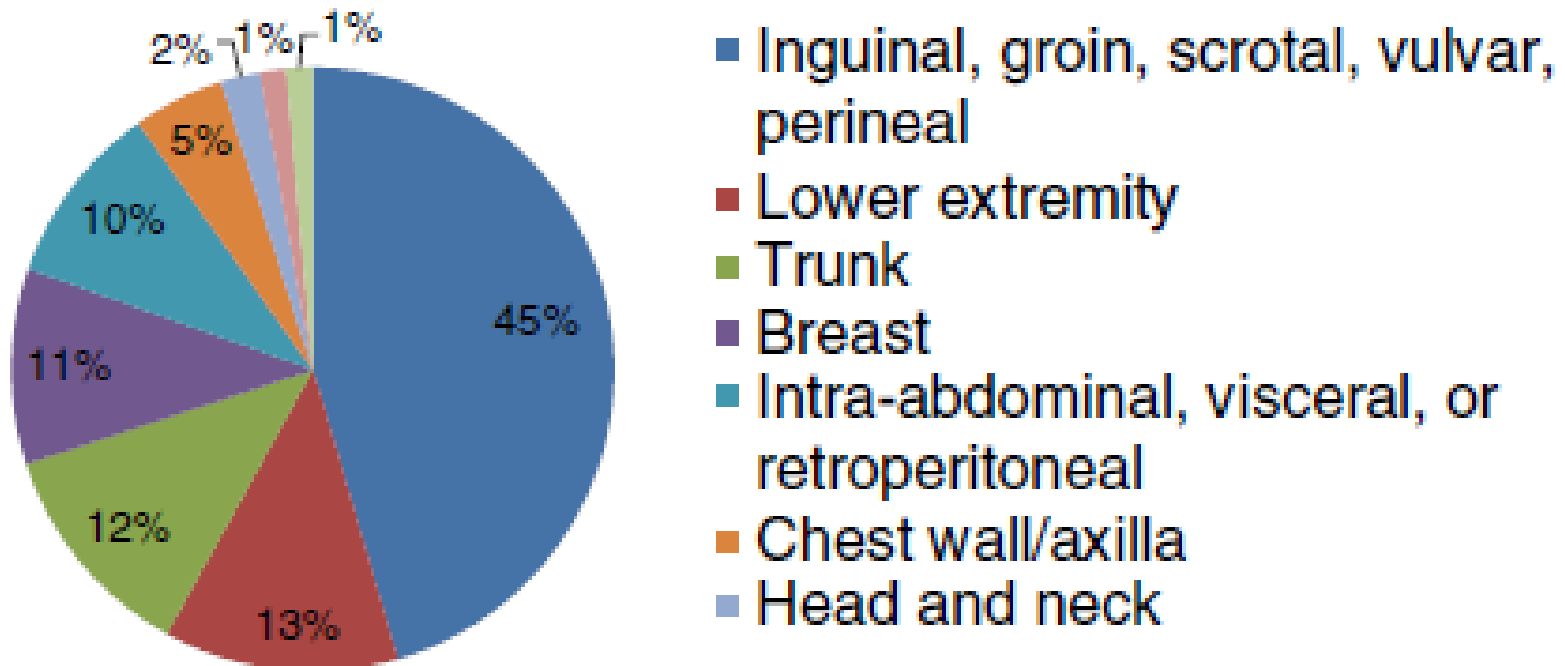
A

### Age Distribution in MTMF



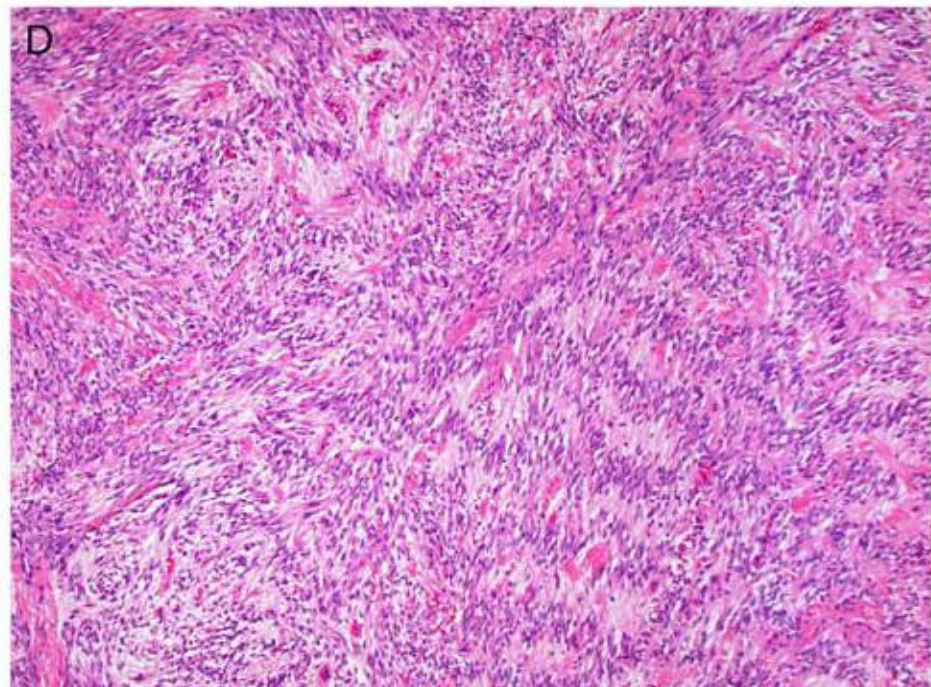
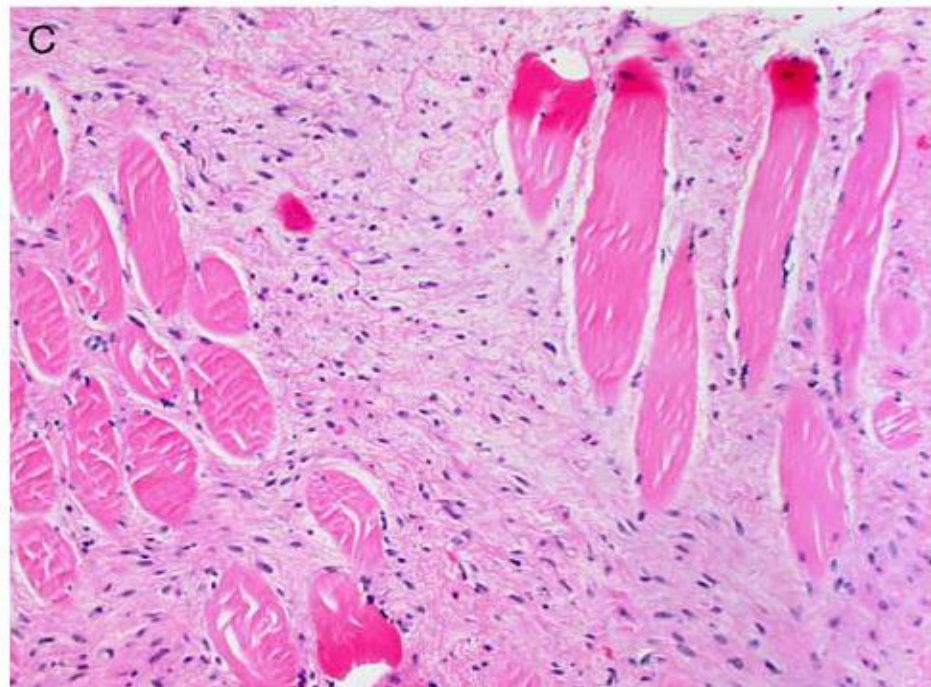
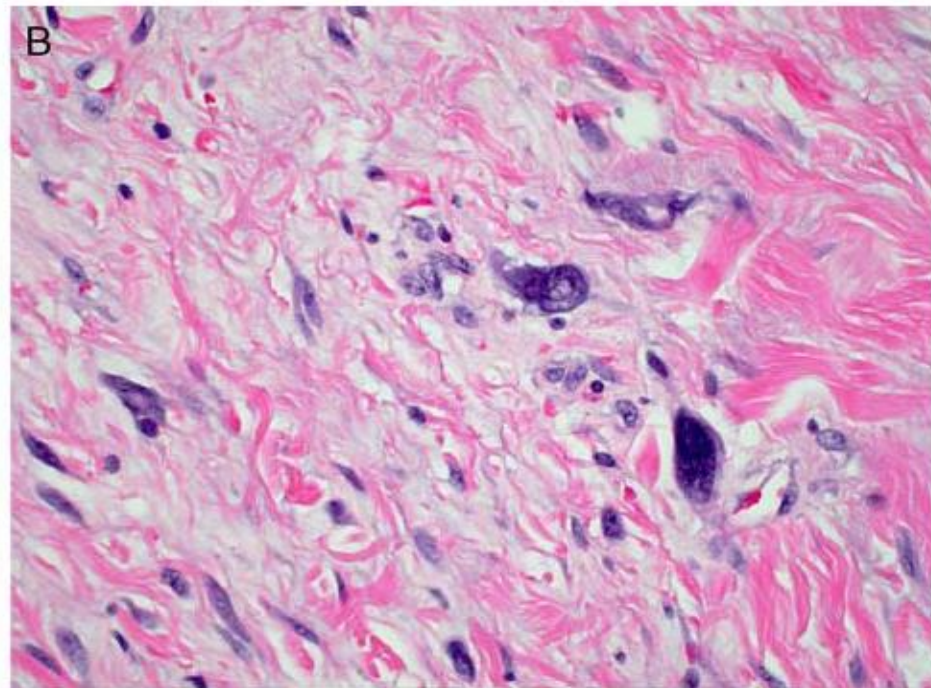
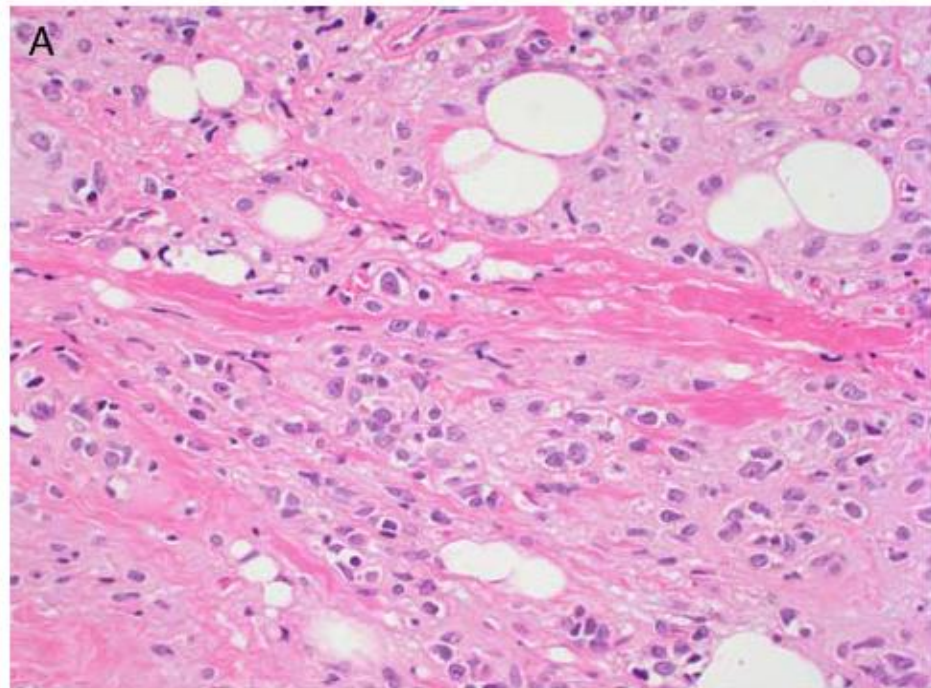
B

## Anatomic Distribution of MTMF



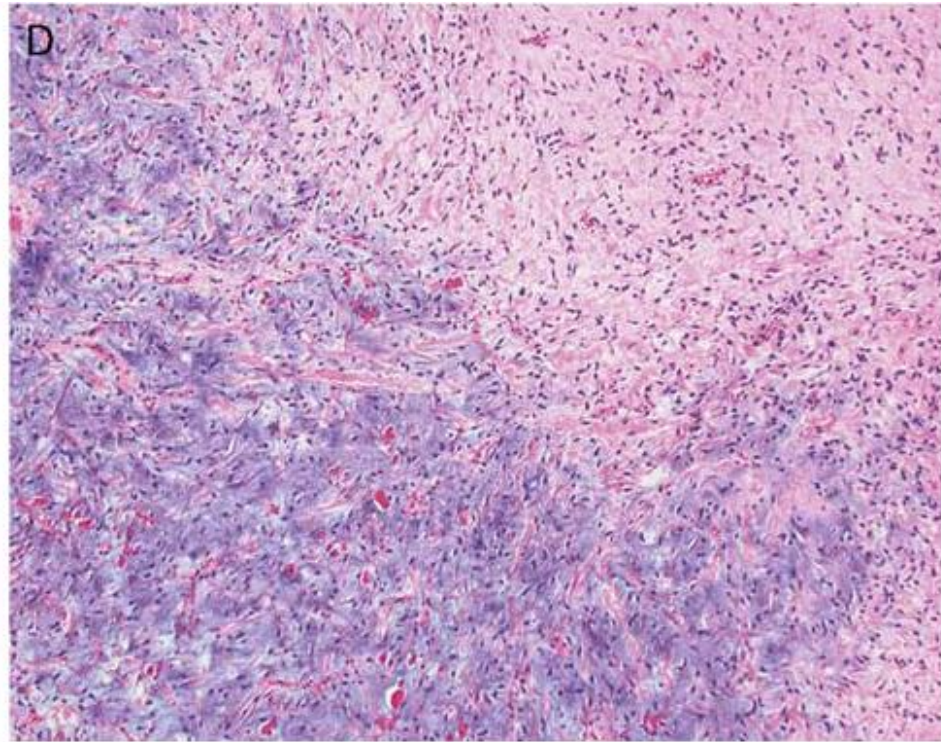
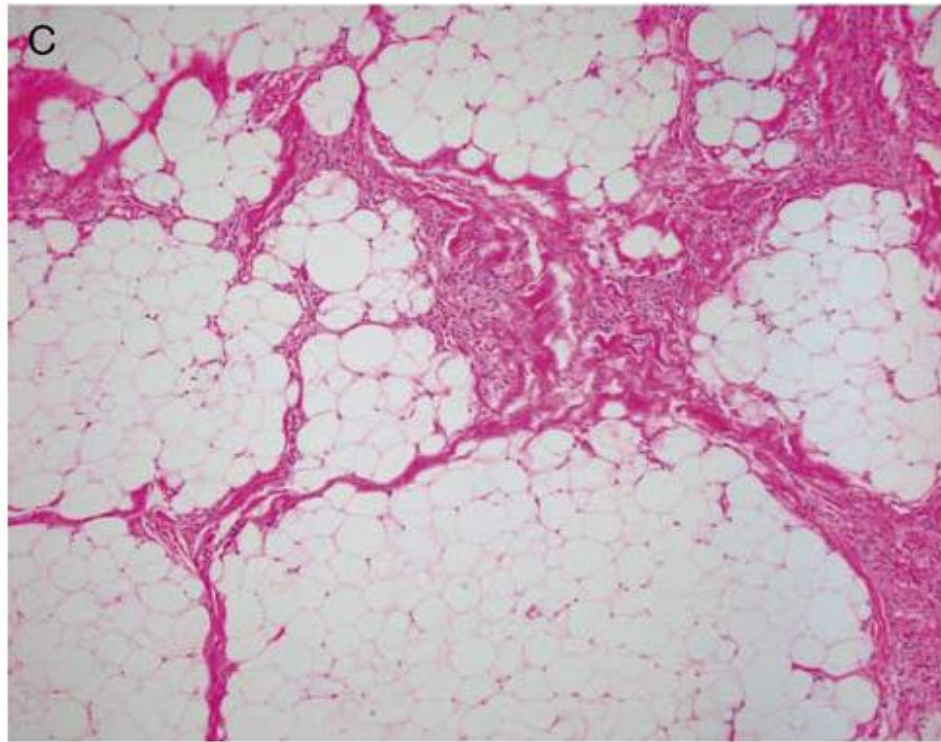
# MTMF

- priemerná veľkosť - 6.6 cm (1 - 22 cm)
- nebolestivé zdurenie (masa)
- vretenovité bunky s relatívne krátkymi jadrami a variabilná adipocytárna zložka
- myxoidna stroma, hyalinizácia, mastocyty
- bez metastazovania
- extrémne nízke riziko rekurencie (v 1 prípade recidíva po 20 rokoch)

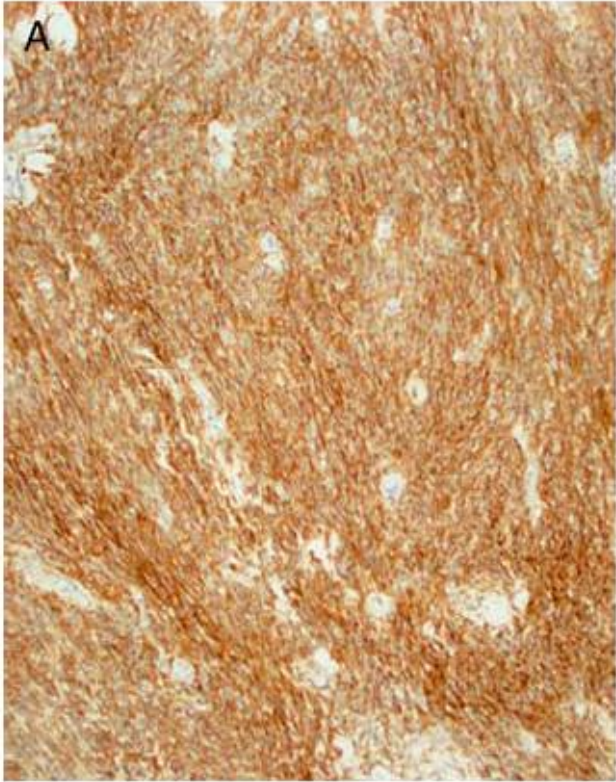




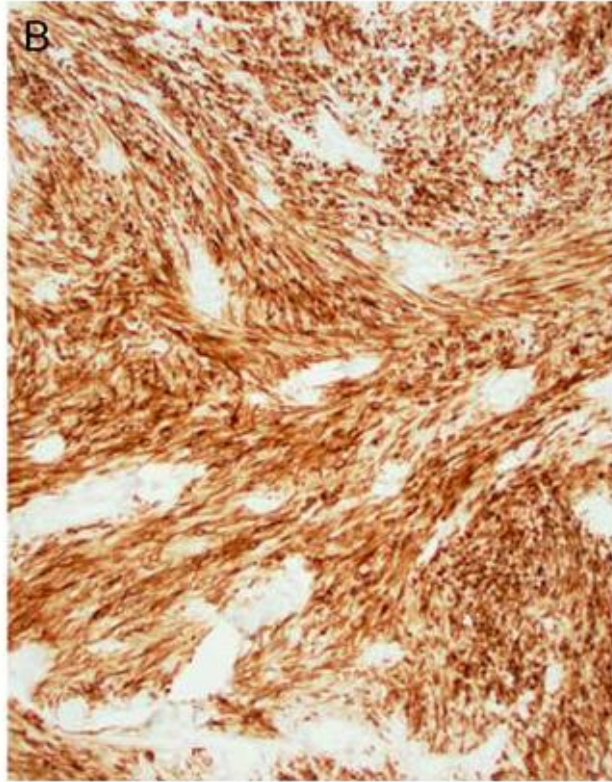
# MTMF



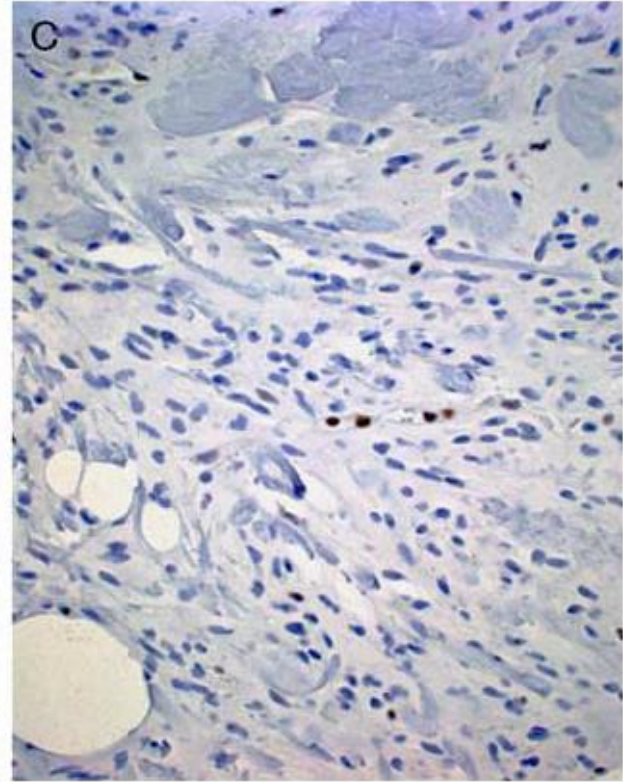
# MTMF



CD34



Desmin



Rb-

## Dif. dg.

- SCL
- ASLT
- Celulárny angiofibróm
- Myolipóm/lipoleiomyóm
- ALT/DDL
- SFT
- Fibromatóza
- GIST

# Záver

1. MTMF má širokú škálu anatomickej lokalizácie, častejší je extramamárny
2. Morfológická variácia MTMF môže spôsobiť diagnostické problémy
3. Hodnotnú pomoc v diagnostike má negatívna expresia Rb
4. Riziko rekurencie je minimálne aj pri pozit. resekčných okrajoch

## Literatúra

1. Wargotz ES, Weiss SW, Norris HJ. Myofibroblastoma of the breast. Sixteen cases of a distinctive benign mesenchymal tumor. *Am J Surg Pathol.* 1987;11:493–502.
2. Maggiani F, Debiec-Rychter M, Verbeeck G, et al. Extramammary myofibroblastoma is genetically related to spindle cell lipoma. *Virchows Arch.* 2006;449:244–247.
3. McMenamin ME, Fletcher CD. Mammary-type myofibroblastoma of soft tissue: a tumor closely related to spindle cell lipoma. *Am J Surg Pathol.* 2001;25:1022–1029.
4. Pauwels P, Sciot R, Croiset F, et al. Myofibroblastoma of the breast: genetic link with spindle cell lipoma. *J Pathol.* 2000;191:282–285.
5. Chen BJ, Marino-Enriquez A, Fletcher CD, et al. Loss of retinoblastoma protein expression in spindle cell/pleomorphic lipomas and cytogenetically related tumors: an immunohistochemical study with diagnostic implications. *Am J Surg Pathol.* 2012;36:1119–1128.
6. Magro G, Foschini MP, Eusebi V. Palisaded myofibroblastoma of the breast: a tumor closely mimicking schwannoma: Report of 2 cases. *Hum Pathol.* 2013;44:1941–1946.
7. McMenamin ME, DeSchryver K, Fletcher CD. Fibrous lesions of the breast: a review. *Int J Surg Pathol.* 2000;8:99–108.

